

PATHOLOGICAL INVESTIGATION OF GOAT LUNGS SLAUGHTERED IN DINAJPUR SADAR

A THESIS

BY

MD. ROFIQUL ISLAM

**REGISTRATION NO.: 1005028
SEMESTER: MARCH - AUGUST/ 2011
SESSION: 2010-2011**



MASTER OF SCIENCE (M. S.)

IN

PATHOLOGY



**DEPARTMENT OF PATHOLOGY AND PARASITOLOGY
HAJEE MOHAMMAD DANESH SCIENCE AND TECHNOLOGY
UNIVERSITY, DINAJPUR-5200**

FEBRUARY, 2012

**PATHOLOGICAL INVESTIGATION OF GOAT
LUNG SLAUGHTERED IN DINAJPUR SADAR**

A THESIS

BY

MD. ROFIQUL ISLAM

**REGISTRATION NO.: 1005028
SEMESTER: MARCH - AUGUST/ 2011
SESSION: 2010-2011**

**Submitted to the
Department of Pathology and Parasitology
Faculty of Veterinary and Animal Science
Hajee Mohammad Danesh Science and Technology University
In partial fulfillment of the requirements
For the degree of**

MASTER OF SCIENCE (M. S.)

IN

PATHOLOGY

**DEPARTMENT OF PATHOLOGY AND PARASITOLOGY
HAJEE MOHAMMAD DANESH SCIENCE AND TECHNOLOGY
UNIVERSITY, DINAJPUR-5200**

FEBRUARY, 2012

PATHOLOGICAL INVESTIGATION OF GOAT LUNG SLAUGHTERED IN DINAJPUR SADAR

A THESIS

BY

MD. ROFIQUL ISLAM

REGISTRATION NO.: 1005028
SEMESTER: MARCH - AUGUST/ 2011
SESSION: 2010-2011

Approved as to style and contents by



(Dr. S. M. Harun-ur-Rashid)
Supervisor



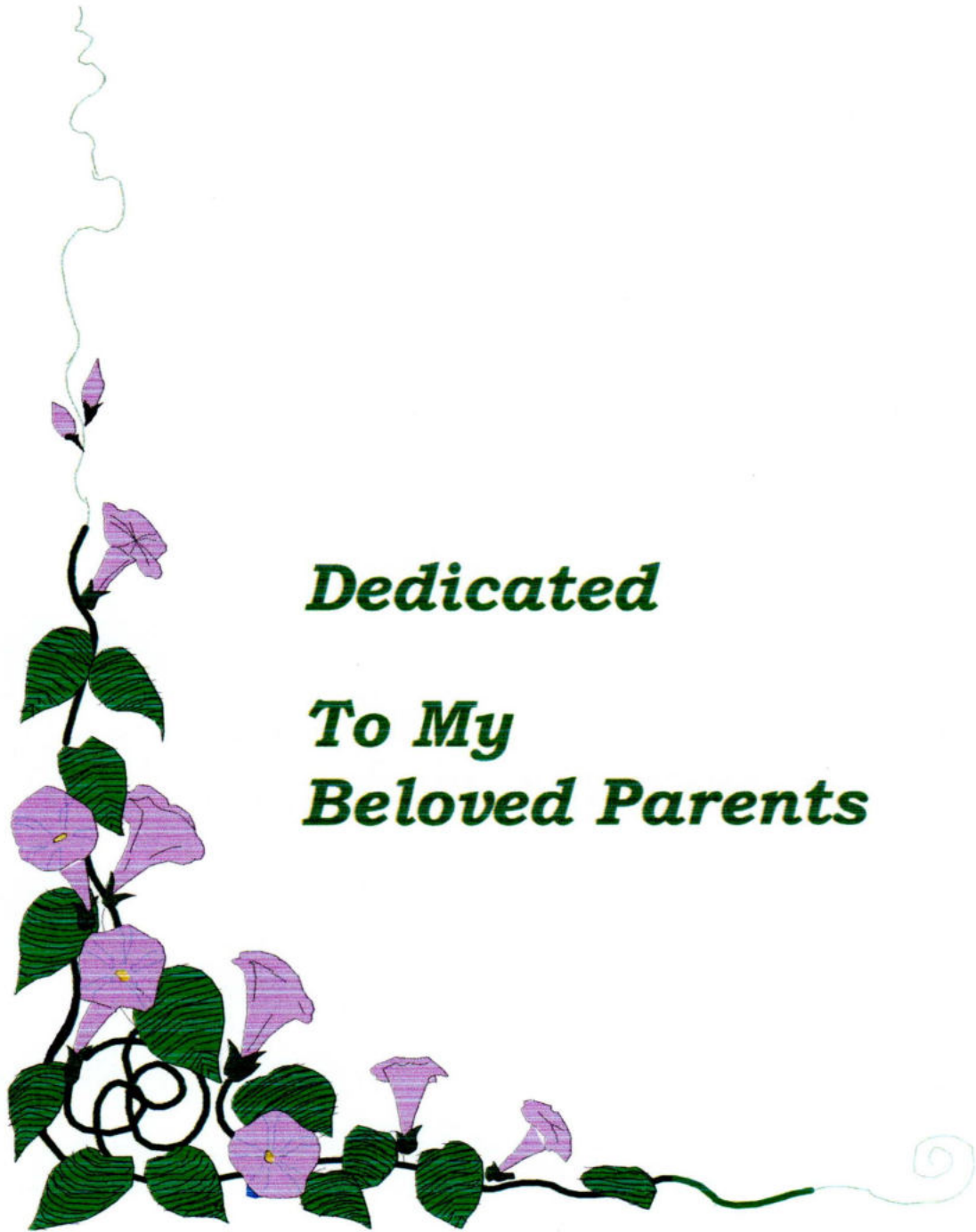
(Dr. Md. Nazrul Islam)
Co-Supervisor



(Dr. S. M. Harun-ur-Rashid)
Chairman
Examination Committee
&
Chairman

DEPARTMENT OF PATHOLOGY AND PARASITOLOGY
HAJEE MOHAMMAD DANESH SCIENCE AND TECHNOLOGY
UNIVERSITY, DINAJPUR-5200

FEBRUARY, 2012



Dedicated

***To My
Beloved Parents***

Acknowledgement

Foremost, I would like to express my sincere gratitude to my supervisor Dr. S. M. Harun-ur-Rashid Chairman Department of Pathology & Parasitology HSTU for the continuous support of my M.S. study and research, for his patience, motivation, enthusiasm, and immense knowledge. His guidance helped me in all the time of research and writing of this thesis.

Heartfelt gratitude and sincere appreciation are extended to my research co-supervisor, Dr. Md. Nazrul Islam, Department of Pathology & Parasitology HSTU for his valuable advice, exclusive suggestions and provisions of facilities and supports needed to complete this research work.

Besides my advisor, I would like to thank the rest of my thesis committee, Dr. Md. Arafatur Rahman, Dr. Md. Mominul Islam, and Dr. Md. Hydar Ali for their encouragement, insightful comments, and hard questions.

My sincere thanks also goes to Dr. Md. Abdur Rahim, and Dr. Md. Mosharrof Hossain for offering me in internship opportunities in their hospitals and leading me working on diverse exciting projects.

Also I thank my friends in HSTU: Dr. Md. Abu Sarforaz Hossain, Dr. Ganapati Ray, Dr. Md. Kamruzzaman, Dr. Md. Abu kayes Bin Aziz, Md. Khademul Islam, and Md. Saiful Islam for their cordial help in completing my MS research.

Last but not the least, I would like to thank my family: my parents Late Ali Hossain and Hasna Begum, for giving birth to me and supporting me spiritually throughout my life.

The author

February, 2012

Abstract

Pathological conditions in the lungs of slaughtered goats were studied. A total of 300 slaughtered goats were examined and among of them 24 lungs were found to be apparently abnormal. The lungs were examined and tissue samples were collected for histopathology in the Histopathology Laboratory of the Department of Pathology and Parasitology, HSTU, Dinajpur. The prevalence of lung diseases was 8%. On gross and histopathological examination lung lesions were categorized into: (1) Purulent pneumonia 1.33%, (2) Interstitial pneumonia 1.00%, (3) Pulmonary hemorrhage 1.67% (4) Fibrinous pneumonia 0.66%, (5) Emphysema 1.00%, (6) Hydatidosis 0.33%, and (7) No major lesions 2.00%. The prevalence of lung lesions or diseases of goat were higher in females (62.5%) than males (37.5%). These findings provide evidence of different lung lesions or diseases in the slaughtered goats in Dinajpur Sadar.

CONTENTS

CHAPTER	TITLE	PAGE
	ACKNOWLEDGEMENT	iv
	ABSTRACT	v
	LIST OF CONTENTS	vi
	LIST OF TABLES	viii
	LIST OF FIGURES	ix
	LIST OF ABBREVIATIONS AND SYMBOLS	x
I	INTRODUCTION	1
II	REVIEW OF LITERATURE	3
	2.1 Diseases caused by Parasites	3
	2.2 Diseases caused by Bacteria	9
	2.3 Diseases caused by Fungus	13
	2.4 Diseases caused by Mycoplasma	14
	2.5 Diseases caused by Virus	16
	2.6 Neoplasms	19
	2.7 Miscellaneous disease conditions	19
III	MATERIALS AND METHODS	22
	3.1 Experimental samples, areas and duration	22
	3.2 Cleaning and sterilization of required glassware	22
	3.3 Histopathology	24
	3.3.1 Materials required for histopathology	24
	3.3.2 Processing of tissue for histopathology	24
	3.3.3 Routine Hematoxylin and Eosin staining procedure	26
	3.4 Staining protocol	27
	3.5 Photography	27

CONTENTS (Contd.)

CHAPTER	TITLE	PAGE
IV	RESULTS	28
	LUNG LESIONS OR DISEASES	29
	4.1 Purulent pneumonia	29
	4.2 Interstitial pneumonia	29
	4.3 Pulmonary hemorrhage	30
	4.4 Fibrinous pneumonia	30
	4.5 Emphysema	31
	4.6 Hydatidosis	31
V	DISCUSSION	38
V	SUMMARY AND CONCLUSIONS	41
VI	REFERENCES	43

LIST OF TABLE

TABLE	TITLE	PAGE
1	The occurrence of different lung diseases or lesions in goat	32
2	The proportional occurrences of different lung diseases or lesions in goat in relation to sex	33

LIST OF FIGURE

FIGURE	TITLE	PAGE
1	Picture of lung collected from goat at Bahadur bazar slaughter house. Grossly pus was found in lung (Black arrow).	34
2	Slide of goat lung showing infiltration of inflammatory cells mainly and few neutrophils within the lumen of bronchiole detected under a high power objective (100X).	34
3	Picture of lung collected from goat at Suihari slaughter house. Grossly pneumonia was found in lung.	35
4	Slide of goat lung showing infiltration of inflammatory cells in the inter-alveolar septa were detected under a high power objective (100X).	35
5	Picture of lung collected from goat at Ramnagar slaughter house. Grossly haemorrhage were found in lung.	36
6	Slide of goat lung showing inflammatory changes in the wall of bronchus detected under a high power objective (100X).	36
7	Slide of goat lung showing network of fibrin associated with a few reactive cells detected under a high power objective (100X).	37
8	Picture of lung collected from goat at Suihari slaughter house. Grossly emphysema was found in lung.	37
9	Picture of lung collected from goat at Birgonj slaughter house. Grossly hydatid cyst was found in lung (Black arrow).	37

ABBREVIATION AND SYMBOLS

°C	: Degree centigrade
%	: Percentage
ACL	: Acral lick dermatitis
<i>et al.</i>	: And his associates
etc.	: Ectetera
ELISA	: Enzyme linked immunosorbent assay
Fig.	: Figure
g	: Gram
H & E	: Hematoxylin and Eosin
HSTU	: Hajee Mohammad Danesh Science and Technology University
lbs	: Pounds
min	: Minute
ml	: Milliliter
mm	: Millimeter
MS	: Master of Science
No.	: Number
OIE	: Office International des Epizootics
PBS	: Phosphate buffered saline
PCR	: Polymerase chain reaction
PD	: Pyotraumatic dermatitis
UV	: Ultraviolet
UK	: United Kingdom
USA	: United States of America
WHO	: World Health Organization
WSPA	: World Society for Protection of Animals

CHAPTER I

INTRODUCTION

Livestock is an important sub-sector considered to be the backbone of Agriculture (Anon., 1988). The magnitude of contribution of the livestock sector to the GDP is about 3% in Bangladesh. It generates about 13% of the total foreign exchange earnings and provides full-time employment of about 25% of the rural populations (Economic survey, 2011). In respect of animal source of protein, Black Bengal goats play a vital role to promote both the health and the wealth of the nations by supplying meat, milk of high caloric value and contributing towards earning a considerable amount of foreign currency by providing skin and its by-products for exports.

There are about 24.50 million goats, 23.40 million cattle and 2.68 million sheep in our country (FAO, 2010). So, goat occupies the first position in livestock population and is called poormen's cow in Bangladesh. It has been estimated that about 10% animals die annually due to diseases and cost benefit ratio had shown to be 1:8 for vaccination and 10: 25 for deworming (Mia and Kibria, 1993). Goat rearing is one of the most important sources of income for majority of rural families in Bangladesh. These animals are mainly maintained by open system grazing on uncultivated lands, roadsides, yards and bank of ponds etc. Even in urban areas, goats are being raised under an intensive management system by stall feeding with bran, fodder and tree leaves.

Black Bengal goats are very popular because of their high quality meat and skin not only in Bangladesh but also in the world market. Farmers are interested in keeping goats due to their polite behaviour, low food intake, highest fertility rate (95%) and multiple kidding efficacies (Islam, 1987). It is quite adaptable to climate variation. This animal is playing a most vital role in the rural economy particularly in the poor section of the population who are mostly keeping these animals as an additional source of their livelihood (Anon, 1988).

It is surprising to note that Veterinarian does not examine our animals before and after slaughter. The indiscriminate slaughterings are done in markets, streets and open fields. So viscera, blood, bones etc. are found here and there. For example, hydatidosis that cause lesions in lungs are capable to transmit in human. So this situation is a serious

threat to human health and environment.

Lung, the important organ of the respiratory system, is vulnerable to many infectious and non-infectious agents causing various diseases and disease conditions. Among the inflammatory or non-inflammatory disease conditions, pneumonia either acute or chronic causes debility and death leading to great economic loss to the farmers and distress women rearing only few goats. Usually, goats are grazed on free pasture, which usually found contaminated with various infectious agents that can get access through inhalation and thus cause pneumonia.

A large number of goats are being brought to the Veterinary clinics for their treatment. Amongst them, a considerable number is of respiratory problem, especially pneumonia. A variety of causes are responsible for development of pneumonia (Rahman *et al.* 1976). The knowledge of pathogenesis, gross and microscopic changes of lung will enable the veterinarians to diagnose the diseases. Related works in the context of Bangladesh on caprine lung lesions is very limited.

Therefore, this investigation has been undertaken to study the lung lesions in goats with the following objectives:

- i) To study the occurrences of different lung lesions.
- ii) To study the gross and histopathologic changes of the diseased lung.
- iii) To study the topographic variation of lung lesions.

CHAPTER II

REVIEW OF LITERATURE

The low production and mortality due to various respiratory diseases are the chief constraints for profitable goat husbandry in many parts of the world including Bangladesh. Goat carcass with major lung lesions may lead to significant economic loss due to condemnation of either whole carcass or lesion containing organ. Apart from economic losses, the most serious and harmful effects of such defects in caprine lungs are the spread of communicable diseases to man. So far, a very limited or no efforts have been executed to diagnose the caprine lung lesions histopathologically in Bangladesh. The available literature on respiratory diseases of goats is reviewed here under the following sub headings.

2.1. Diseases caused by Parasites

Smith et al. (1972) reported that the hydatid cysts had the tendency to produce endogenous daughter cysts, which displaced the vital tissues. The growths of cysts were slow and the cyst was encapsulated by dense fibrous tissue of the host. The larva had an outer dense laminated wall without nuclei, which enclosed a germinal layer and from the later brood capsules arose.

Smith et al. (1972) described the gross and microscopic lesions of Dictyocaulosis. It occurred naturally in many animals including sheep and goats and the gross lesions were hemorrhage, consolidation and sometimes the adult lungworms were found to be deposited in "head down" position upon the exudate within the bronchioles. Emphysema was common in unconsolidated parts of the lungs. They stated that the entire lobules became filled with leukocytes, among which eosinophils predominated.

Romboli et al. (1975) found *Cysticercus tenuicollis* infection in the lungs of lambs. They examined the infected lungs both grossly and histopathologically and had seen the reactive changes in the alveolar tissue and also in the tract traversed by the larvae.

Rahman et al. (1975) examined 13000 carcasses of goats at three abattoirs in Bangladesh. The identified diseases were largely parasitic viz. Fascioliasis 9-17%, Oesophagostomiasis 35-65%, Cysticercosis 55- 77%, Hydatidosis 12-20%. However, a condition with soft nodules in the lungs and intestines affecting up to 7% of the animal was not identified.

Ray et al. (1978) reported the occurrence of larval cestodes in goats in 3 slaughterhouses in the Tarai region of Uttarpradesh, India. Hydatid cyst was found in 3 of 350 goats in Bereilly, 1 of 325 in pantnagar and 2 of 25 in Haldwani. *Cysticercus tenuicollis* was found in 37 of 350, 41 of 325 and 4 of 25 cases, respectively. Multiceps cysts were found in 3 of 325 goats at Pantnagar.

Paul et al. (1978) studied the incidence of parasites in the lungs of 46 adult sheep slaughtered at abattoir. They observed that the *Protostrongylus* infection gave rise to fewer granulomatous elements than *Muellerious* and *Cystocaulus* infection. In advanced cases, they found pulmonary sclerosis with the development of fibrous and muscular tissue.

Dada et al. (1979) reported that 35 (18.4%) of 190 goats were harboured hydatid cysts in Kaduna state of Nigeria. The lungs were the most usual sites for such infection.

Sadana et al. (1980) studied the incidence and pathology of verminous pneumonia in sheep and goats. They detected *Protostrongylus sp.* and *Dictyocaulus filaria* in the lung of 649 (5.7%) out of 11453 sheep and goats. The prevalence of parasitic pneumonia was 11.5% in December and decreased to 2.7% in May. The gross and microscopic lesions in the lungs of sheep and goats were similar in both the infections.

Verma (1980) found that 6.88% of the animals slaughtered in Bareilly, India, harboured hydatid cysts. He found that 103 of 928 buffaloes, 18 of 386 sheep, 11 of 362 goats were infected. Eight cysts of goats were fertile and most of the cysts were recovered from the lungs.

Islam (1981) studied on hydatid disease of goats in Bangladesh. Of 12344 examined goats of different ages from various localities of Bangladesh, 1024 (8.29%) were found to be infected. The incidence of infection was 36.73% in liver, 32.03% in lungs, 4.69% in spleen, 3.13% in heart, 1.56% in kidney, 0.78% in omentum and 21.09% occurring in the liver and the lungs. He also recorded the incidence of infection in different age groups and they were 0.63% in animals up to 1 year, 2.48% between 1 and 2 years, 5.53% between 2 and 3 years, 16.80% between 3 and 5 years and 21.64% on and above 5 years.

Ashraf et al. (1986) worked on incidence and pathology of lung affected with tuberculosis and hydatidosis in sheep and goats. Diseased lungs from 100 sheep and 100 goats were collected at Faisalabad abattoir. Tuberculous lesions were found in 2 sheep but not in goats. Hydatid cysts were found in 24 sheep and 19 goats.

Iqbal et al. (1987) studied the incidence of hydatidosis in Teddy breed of goats in an abattoir of Faisalabad in Pakistan. The presence of hydatid cyst was detected in 80 of 1000 animals. Such cysts were found in 4.6% of 655 male and 14.5% of 345 female goats. These were mostly detected in the lungs.

Lorenzini and Ruggieri (1987) worked on a questionnaire survey of 99 slaughterhouses in the principal provincial towns of Italy. The authors showed that for 1979-1983 the unilocular hydatid prevalence rates varied from 4.5% to 5.4% for sheep and goats, 0.5% to 0.7% for cattle, 0.2% to 0.4% for pigs and 0.1% to 0.3% for horses. Considerable differences in hydatid prevalence in sheep and goats were noted in different regions. The liver was more frequently affected than that of lungs and spleen. Seven cases of suspected alveolar hydatids of lung were also reported.

Singh and Dhar (1988) reported that 48.1% of 754 buffaloes, 30.5% of 3987 sheep and 21.0% of 2133 goats from northern India were found to be infected with larval *E. granulosus*. The prevalence of infection in buffaloes increased with increasing age. The lungs and livers appeared to be the sites of predilection. 71% of cysts from buffaloes were sterile, whereas, 90% of cysts from sheep and goats were fertile.

Verma and Ahluwalia (1991) studied on 2800 domestic animals examined at different locations in central and western Uttar Pradesh, India, of which 232 (8.28%)

harboured hydatid cysts. The Prevalence of *Echinococcus granulosus* infection was 15.76% in buffaloes, 3.52% in pigs, 2.74% in sheep, and 2.65% in goats. Hydatid disease was confined to the lungs (43.0%), liver (24.3%), heart (1.65%), kidney (1.63%), and omentum and reproductive organs (4.42%) in buffaloes. The involvement of the lungs was highest in sheep (69.23%) and buffaloes (43.1%), while the liver was predominantly infected in goats and pigs. Out of 193 stray dogs examined, 41 (21.24%) were infected.

Hussain et al. (1992) studied on prevalence and organ specificity of hydatidosis in 5000 buffaloes, 4000 cattle, 4000 sheep and 3000 goats of different age and sex from slaughterhouses in Pakistan. The incidence of cysts in calves of buffaloes and cattle was 9.87% and 7.36%, respectively. Lambs and kids were not infected. Over all, the infection rate in females (36.82%) was slightly higher than in males (34.93%). In buffaloes and cattle, the liver was the most frequently infected organ and the rate of infection was 51.20% and 49.84%, respectively, whereas in sheep and goats the lungs were more commonly affected organ and the rate of infection were 6.60% and 63.07% respectively.

Shanmugam et al. (1993) studied on the incidence of hydatidosis in sheep and goats in Mettur town. Of 1074 sheep and 614 goat carcasses examined for the presence of hydatid cysts, 302 sheep (28.12%) and 238 goats (38.76%) were positive. In both species, most commonly affected organs by cysts were lungs, liver and abdominal cavity. The majority of cysts were fertile, multiple and unilocular.

Anwar et al. (1993) analysed the abattoir records in order to determine the prevalence and fertility of hydatid cysts in sheep and goats in Pakistan. The authors examined the lungs, liver and spleen of 28965 goats at Faisalabad abattoir during the period of 1986 to 1988 which revealed hydatid cysts in 1.57% male sheep, 4.95% of female sheep and in none of the 569 lambs. The prevalence of hydatid cysts in goats was 0.55 % and 0.21% respectively in male and female and none of the 3207 kids were infected. The overall prevalence of hydatid disease in sheep and goats was 0.98%. The fertility ratio of hydatid cysts was 80.95% and 65.49% for sheep and goats, respectively.

Umur and Aslantas (1993) worked on prevalence and economic importance of hydatidosis in ruminants slaughtered in Kars municipality slaughterhouse between

January and December 1992. The livers, lungs, spleens and hearts of 5813 cattle, 2742 sheep, 215 goats and 138 water buffaloes slaughtered at the municipal slaughterhouse in Kars, Turkey, were examined. Hydatid cysts were found in 48.35% of sheep, 25.11% of goats, 24.65% of cattle and 16.66% of water buffaloes. In sheep, the cysts were found mostly in the livers, but in the other species they were found mostly in the lungs. The economic loss from discarded lungs and livers in 1993 was estimated to be about Tk 170 million.

Himonas et al. (1994) studied that the viability of hydatid cysts (*Echinococcus granulosus*) in animals slaughtered in the abattoir of Thessaloniki, Macedonia, Greece. Two hundred sheep (infection prevalence, 100%), 106 cattle (56.6%), 203 pigs (9.3 %) and 52 goats (15.4%) were examined. All fertile cysts contained viable protoscoleces. In sheep, there was a mean of 1.1 (29.8% of total cysts) fertile cysts per animal containing 297.3 (81.3%) viable protoscoleces. The rate of viable protoscoleces in the lungs was 82.3% and in the liver 71.2%. In cattle there was a mean of 0.1 (6.6% of total) fertile cysts per animal containing 46.4 (72.2%) viable protoscoleces. The rate of viable protoscoleces in the lungs was 69.5% and in the liver 87%. In pigs there was a mean of 0.02 (0.5% of total) fertile cysts per animal containing 32.0 (76.8%) viable protoscoleces. The rate of viable protoscoleces in the lungs was 97.1% and in the liver 68.9%. In goats there was a mean of 0.1 (12.5% of total) fertile cysts per animal containing 12 (54.6%) viable protoscoleces. The percentage of viable protoscoleces in the lungs was 54.4% but no fertile cysts were found in the liver.

Masduzzaman (1995) reported the organ wise distribution of hydatidosis in different abattoirs of Mymensingh, Chittagong and Kishoregonj (Bangladesh). The author examined 1129 goats and found hydatidosis in 72.29% of lungs, 45.89% of liver and 0% of spleen, respectively

Singh et al. (1995) worked on incidence and pathomorphology of pulmonary schistosomiasis in sheep and goats. Pneumonic lungs were identified in 351 of 3308 sheep and 249 of 4108 goats slaughtered at abattoirs. *Schistosoma indicum* was identified in the pneumonic lungs of 19 sheep and 23 goats.

Dadhich and Sharma (1996) worked on Incidence and pathology of pulmonary schistosomiasis in goats at Rajasthan. Gross lesions were observed in 571 of 2217 lung

specimens. Pulmonary schistosomes were found in 12 cases (2.10%). Microscopy revealed large number of *Schistosoma indicum* ova.

Oge et al. (1998) worked on 2484 sheep, 311 goats and 1941 cattle slaughtered at 3 abattoirs in Ankara province for examination of metacestodes viz. hydatid cysts of *Echinococcus granulosus*, *Cysticercus tenuicollis* of *Taenia hydatigena*, and *Cysticercus bovis* of *Taenia saginata*. The prevalence of infection was 33.9%, 29.5% and 9.8% in sheep, goats and cattle, respectively. *T. hydatigena* had the highest prevalence (28.0% in sheep, 27.9% in goats and 0% in cattle), followed by *E. granulosus* (7.2%, 1.6% and 9.4%) and *T. saginata* (0%, 0% and 0.4%). Mixed infections were seen in sheep and cattle, but not in goats. The maximum intensity of *T. hydatigena* was observed in the mesenteries and omentum. Hydatid cysts were found mostly in the liver and lungs, and *T. saginata* in the heart and skeletal muscles.

Gabriele et al. (2003) studied an epidemiological survey of hydatidosis (*Echinococcus granulosus*) of livestock in Sardinia, Italy, from 1988-1989. The viscera of 7120 sheep, 5147 cattle, 748 pigs and 667 goats were examined. Considering only female animals, 86.9% of 6945 sheep, 24.3% of 667 goats, 28.5% of 2415 cattle and 20.3% of 502 pigs were infected. Infection rates for animals >2 years of age were 87.9% of 6804 sheep, 24.5% of 550 goats, 52.1% of 1070 cattle and 41.7% of 96 pigs. Sheep and pigs had the highest prevalences of fertile cysts 39.9% and 35.3%, compared with (that of 21.2% and 24.7% for goats and cattle, respectively. Cattle had the highest proportion of infection both in liver and lungs (76.1%) and these organs had more than 10 cysts (56.2%). In males, for all species, the prevalence was lower than in females, although the infection trend was similar.

Jarjees et al. (2005) studied over a period of 12 months at Mosul abattoir, Iraq of 24515 sheep, 4162 cattle and 4086 goats for the occurrence of hydatid cysts. The occurrences were 2437 (9.94%) in sheep, 372 (8.93%) in cattle and 252 (6.16%) in goats of livers and/or lungs. Fertility rates of cysts from sheep, cattle and goats were 1626 of 2437 (66.7%), 88 of 372 (23.6%) and 51 of 252 (20.2%), respectively. Livers were more frequently affected than lungs.

Das and Sreekrishnan (2007) reported for first time, the prevalence of *Echinococcus granulosus* infection in sheep and goats in pondicherry, India. A survey

from November 1995 to March 1997 revealed infection in 47.64% of 680 and 37.84% of 325 goats and sheep, respectively. In sheep the highest infection was in the lungs (35.85%) followed by the liver (24.25%), the heart (12.30%) and the spleen (2.02%). In goats, infection was highest in the lungs (32.0%) followed by the heart (14.75%); no infection was seen in the spleen. Seasonally the highest prevalence was from May to July (40%) followed by August to October (27%), and least in November to January (2.02%). In sheep 78% and in goats 82% of cysts were fertile.

Sobein et al. (2009) studied on public health importance of hydatid cysts in slaughtered sheep, (88) and goats, (771) at Gassim abattoir over 18 months from May 1995 to November 1996. The infection rate of sheep was 2.5% (local breeds 2.41%, foreign breeds 2.58%) and 5% of goats (local breeds 3.65%, foreign breeds 6.72%). Organs affected included liver 58.89%, lungs 8.29%, heart 0.96%, quarters 10.05% and other sites 21.78%. The public health significance and preventive measures were discussed.

Utpal et al. (2009) studied on cystic hydatidosis of food animals in greater Calcutta for a period of one-year. The carcasses of 5414 cattle, 4212 buffaloes, 230 sheep, 410 goats, and 105 pigs were examined for hydatid cysts; 45%, 48%, 9%, 5% and 8%, respectively were positive. In all species the most common sites were the liver and lungs, but cysts were also found in the spleen of 4 and the kidneys of 3 animals. The cysts were sterile in 95% of the cattle and 88% of the buffaloes, but most of those in the other species were fertile. The public health significance of the findings was emphasized, with reference being made to the free access allowed to dogs, which might take infected offal from the carcasses in the abattoirs.

2.2. Diseases caused by Bacteria

Sarker and Battacharyya (1975) found that out of 98 recently purchased black Bengal goats, 30 died of purulent pneumonia due to *Corynebacterium ovis* infection. Grossly there were multiple abscesses of varying size with the adhesion of pleura, collapse of alveolar walls and accumulation of exudate in the air passage and patchy distribution of numerous micro-abscesses with predominant mononuclear cells infiltration.

Kapur et al. (1976) reported gastroenteritis and pneumonia as the most important causes of mortality in 98 lambs and 14 kids over a two years period. *Escherichia coli* was the most important agent.

Ojo (1976) recorded the incidence of pneumonia amongst slaughtered goats. The predominant isolates, from healthy and pneumonic goats were *Pasteurella* and *Mycoplasma*. In the normal respiratory tract the isolates were *Pasteurella* and were 5% in nasopharynx, 10% in lungs and 15% in trachea. *Mycoplasmas* were isolated only from nasopharynx (about 20%). From pneumonic lungs, the isolates were also *Pasteurella* : nasopharynx (35%), lungs (40%) and trachea (41%); *Mycoplasma* was only found in lungs (30%).

Sharma and Dwivedi (1977) studied the pseudotuberculosis histopathologically, which was caused by *Corynebacterium ovis* in the lungs and lymph node of sheep and goats. They grossly found discrete and extensive areas of consolidation with raised sub-pleural or deep-rooted, greenish-yellow encapsulated nodules (about the size of a walnut) embedded in the lungs. Caseo-purulent material occupied the extensive areas. Microscopically, they observed the caseous necrosis, fragmented nuclear debris, degenerated and intact neutrophils surrounded by macrophages, lymphocytes and giant cells, encircled with proliferating fibroblast. The tuberculous bacteria could not be demonstrated, the erroneous conclusion often reached that the lesions were due to tuberculosis but they supported the term pseudotuberculosis for *Corynebacterium ovis* infection.

Thurley et al. (1978) examined a group of lambs and they isolated *Pasteurella haemolytica* and *Mycoplasma* from the affected lungs. In those cases the typical lesions of enzootic pneumonia were seen.

Ugochukwu (1986) examined bacteriologically 100 pneumonic lungs of goat. These yielded 75 cultures of bacteria, comprising 45 isolates of *Streptococcus*, 25 of *Staphylococcus*, 3 of *Corynebacterium* and 2 of *Pasteurella*. He isolated four isolates of *Corynebacterium pyogenes* from 350 lungs with pneumonia. This bacterium was associated with supportive pneumonia accompanied by infiltration of polymorphs.

Midwinter (1986) reported 11 isolates from lungs of goat with acute pneumonia in four districts of New Zealand, among which nine were *Pasteurella haemolytica* serotype A₂, and one A₇.

Almeida et al. (1986) surveyed on the bacterial agents associated with respiratory diseases of goats in North Eastern Brazil. Lungs from 76 goats died with respiratory disease over a 12 month period were examined bacteriologically. The principal isolates were *Pasteurella haemolytica* (from 35.5% of goats), *Corynebacterium pseudotuberculosis* (13.3%), *C. pyogenes* (7.9%), *Corynebacterium sp.* (6.6%) *Pasteurella sp.* (5.3%), *Pseudomonas sp.* (5.3%), *Staphylococcus sp.* (3.9%) and *Streptococcus sp.* (2.6%).

Gezon et al. (1988) reported that *Mycobacterium paratuberculosis* infection in 2 goats in 1974 and in 5 goats in 1975; 5 of which were from a single herd, pathological studies revealed gross and microscopic lesions predominately in the lower portion of the ileum and lesions were detected in the entire intestinal tract, liver, spleen and lungs.

Hayashidani et al. (1988) worked on an outbreak of pneumonia occurred among shiba goats on a farm in Fuchu, Tokyo several days after the introduction of 4 shiba saanen goats into the farm. Nine of the goats on the farm died during the outbreak. Necropsy examination of these 5 goats showed lesions of fibrinous pneumonia. *P. haemolytica* biotype a serotype 2 was isolated from the lungs of 2 goats. Twenty four days after the first death a serological study of goats on 2 farms showed that on the affected farm in Fuchu 6 (40%) of 15 goats had low *P. haemolytica* antibody titres but on the farm of origin of the introduced goats in saitama 25 (83%) of 30 goats had relatively high *P. haemolytica* antibody titres.

Jubb, et al. (1993) described the pneumonic pasteurellosis in goats. In goat kids, a small outbreak of acute pneumonia and pleuritis was caused by *Pasteurella haemolytica*. At post-mortem, a sheet of yellow fibrin was loosely adherent to the pleural surfaces and between the cranial lobes of the lungs. These lobes were voluminous, firm, and dark red, with a transition to less firm tissue with mottled gray pink discoloration in the caudal lobes.

Radostits et al. (1994) described the *Pasteurella haemolytica* induced pneumonic pasteurellosis in sheep and goats. In sheep that had died from peracute pneumonic pasteurellosis there was greenish gelatinous exudate over the pericardium and large quantities of straw-colored pleural exudate. The lungs were enlarged, edematous and hemorrhagic. With less acute cases there was consolidation of the lung, usually the apical and cardiac lobes but occasionally in the diaphragmatic lobe. The affected lung was hepatized and clearly demarcated. Histologically, there was diffuse alveolar necrosis, edema of interlobular septa, sloughing of bronchial mucosa, and in sheep that survived the peracute phase of the disease there were so-called oat cells in zones surrounding the necrotic alveoli.

Zamri et al. (1996) studied on a model of pneumonic pasteurellosis in goats using *P. multocida* harvested from pneumonic lungs of goats (types A and D), rabbits (type A) and sheep (type D). The resultant infection were acute, subacute or chronic. The gross and histological lesions of the subacute and chronic infections were typical of pneumonic pasteurellosis. *P. multocida* type D, produced significantly more severe lesions when compared with other isolates. There were strong correlation between the clinical signs and the severity of lesions.

Scholes and Kelly (1997) studied on goat that developed acute fibrinous pleuropneumonia associated with *Pasteurella haemolytica* infection that developed thrombotic occlusion of a large pulmonary vein. Thrombosis of pulmonary capillaries occurred in pneumonic pasteurellosis, but large vessels were not commonly affected. It was suggested that this unusual lesion might reflect the procoagulant effect of *Pasteurella* endotoxin on vascular endothelium. An incidental observation was the presence of myocardial-type muscle fibers in the tunica media of the pulmonary vein.

Dadhich and Sharma (1998) described pathological observations of purulent pneumonia in goats. Lungs were collected from goats at abattoirs in Rajasthan, where purulent pneumonia caused high mortality. The disease was found in 1.58% of the 2217 examined lungs. Of which 571 specimens were examined histologically and the main pathological changes were described. Gram-positive bacteria morphologically indistinguishable from *Corynebacterium* were seen in stained tissue sections.

Aiello and Mays (2001) described the lung lesions of pneumonic pasteurellosis in sheep and goats. The lesions were confined to the cranioventral lung lobes on both sides. These areas appeared red to purple and felt firm from consolidation. The pleural cavity contained variable amounts of straw-colored fluid, and yellow fibrin covered the pleural surface of affected lung lobes from pleuritis. In chronic cases, there were extensive pleural adhesions and multiple abscesses of variable size.

Kamvar et al. (2003) worked on pneumonic *pasteurellosis* in goats. A total of 9432 goat lungs were examined at various abattoirs in India between March 1995 and May 1996. Pneumonic lesions were detected in 374 samples. Acute fibrinous bronchopneumonia was diagnosed in 99 goats, haemorrhagic pneumonia in 10 goats and necrotizing bronchopneumonia in 21 goats. *Pasteurella sp.* was isolated from 34.75% of affected goats. This organism was also involved in the etiology of chronic non-supportive bronchopneumonia (5.36%), and interstitial pneumonia (63%). *Pasteurella multocida* was more frequently isolated than *P. haemolytica*.

Tkachuk et al. (2007) studied on the clinical history and pathology of 6 goats with *Rhodococcus equi* infection between 1993 and 1996. The most common lesions seen on necropsy examination of the 6 goats was multifocal, well encapsulated granulomatous or caseous abscesses in the liver with smaller number of similar abscesses in the lungs, and the spleen in some. A large, 85 kb plasmid was isolated from the isolated goat, which showed a type I EcoR I digestion pattern. It reacted with monoclonal antibodies to both vapA and the intermediate virulence associated protein. This was apparently the first report of recurrent *R. equi* infection in a goat herd.

2.3 Disease caused by Fungus

Gajendragad et al. (1986) a case of sporotrichosis in a goat. At necropsy the lungs were found to be congested and oedematous. A growth in the trachea yielded a fungus with the characteristics resembling *Sporotrichum schenckii*. Attempts to isolate the fungus from lung tissue was unsuccessful.

Sing et al. (1995) examined the lungs of 1125 sheep and 3447 goats slaughtered in Uttar Pradesh. Aspergillosis was diagnosed in 6 (0.53%) sheep and 10 (0.29%) goats. *This was considerably higher than previously reported.*

Dadhich and sharma (2001) reported that the incidence and pathology of mycotic pneumonia in goats from Rajasthan. Mycotic pneumonia was recorded in 0.53% of 2217 lung specimens examined.

2.4. Diseases caused by Mycoplasma

Livingston (1975) isolated mycoplasmas from pneumonic lesions of 39 cases out of 40 lambs collected from the slaughter houses in San Angelo, He found two distinct types of colonies produced by these mycoplasmas and also isolated some bacteria such as *Pasteurella*, *Staphylococci* and *Streptococci* from the same lambs.

Kaliner and Macowan (1977) worked on both natural and experimental contagious caprine pleuropneumonia of goats in Kenya. The pulmonary lesions were those of focal fibrinous pleuropneumonia with variable involvement of interstitial connective tissue.

Stipkovits and Schimmel (1978) examined the lungs, nasal mucosa, lymph nodes of lungs, heart and brain from pneumonic sheep of 6-9 months of age. They found *Mycoplasma ovipneumoniae* only from an affected flock and concluded that the disease of the respiratory organs resulted from *Mycoplasma ovipneumoniae* infection.

Carter and Chengappa (1993) worked on mycoplasma infections of sheep and goats. Contagious caprine pleuropneumonia (acute serofibrinous pleurisy and pneumonia) which involved almost entire lobes and were characterized by red and gray hepatization with characteristic hemorrhagic infarction.

EL- Manakhly (1995) studied on an outbreak of mycoplasmal infection with respiratory signs occurred in a flock of 35-balady goats aged between 4 to 6 year old kept at Alexandria University. The mortality rate was 20%. *Mycoplasma mycoides* was isolated from most of samples taken from both dead and live animals. Few isolates of *Pasteurella multocida*, *Salmonella sp.* and *Escherichia coli* were present. Specimens were collected from the lungs, intestine, kidneys, liver, heart, brain, spleen, oesophagus and mesenteric lymph nodes. Pulmonary congestion, wetness and consolidation with or without hyperaemia of the duodenum, and congestion and enlargement of the kidneys were observed. Microscopically, there was catarrhal bronchopneumonia, atelectasis and emphysema in the lungs.

Rodriguez et al. (1995) reported that, a goat pleuropneumonia outbreak occurring in a herd of 800 animals in the province of Ciudad Real Spain. Severe respiratory signs and high mortality were the most significant observations. The adult goats presented mainly respiratory symptoms. The most significant lesions were found in the thoracic cavity. Macroscopically, a focal extensive fibrinonecrotic pleuropneumonia was seen and the histopathological analysis confirmed fibrinopurulent and necrotic pleuropneumonia with areas of acute pyogenic bronchopneumonia. Microbiologically, the mycoplasmas grew rapidly (18-24 h.) and after 48 hour there were colonies of 1-1.5 mm diameter in size.

Jha and Beier (1996) studied on respiratory diseases, with special reference to mycoplasmosis in goats in the eastern hills of Nepal. Among the diseases of goats reported by the farmers in the eastern hills. 23.3% of cases were respiratory problems. The analysis of goat postmortem records of Pakhribas Agricultural Centre (PAC) showed that deaths due to pneumonia were 31.6% of all deaths. None of the bacterial species isolated from the lung samples of the goats at PAC, except *Pasteurella haemolytica* (5.2%), were considered as major cause of pneumonia. An attempt was made to isolate mycoplasmas from the goats of the PAC livestock farm and from village goat flocks. One hundred and thirty-six nasal swabs from goats having purulent/serous nasal discharge and nine lung and pericardial fluid samples from postmortem cases were collected and subjected to mycoplasma isolation at PAC Veterinary Laboratory. Thirty-five nasal swabs and four lung and pericardial fluid samples were found to be positive for mycoplasmas. With further laboratory confirmation and species identification at the Federal Institute for Health protection of Consumers and Veterinary Medicine, Jena, Germany, eight samples have been identified to date. The identified species are *Mycoplasma mycoides subspecies mycoides* (LC), *Acholeplasma laidlawii* and *Mycoplasma arginini*. This was first time that the presence of mycoplasmas in goats of Nepal had been confirmed.

Oros et al. (1997) studied on respiratory systems from 83 goats (33 kids and 50 adults) from a flock with a history of pleuropneumonia caused by mycoplasmas. A total of 82% (27/33) of kids and 36% (18/50) of adult goats had pulmonary lesions characteristic of enzootic pneumonia. The following *Mycoplasma spp.* were identified; *M. mycoides subsp. mycoides* (Large Colony) (3.7%; 1/27) *M. arginini* (3.7%; 1/27) and

other *Mycoplasma sp.* (7.4%: 2/27). *Pasteurella multocida* (14.8%: 4/18) was found associated with enzootic pneumonia lesions in younger animals.

Petsaga et al. (2000) reported that *M. mycoides subsp. capri* and *M. capricolum* were isolated from the lung and joints of goats involved in 1 of 11 mtbreaks of pleuropneumonia.

Gutierrez et al. (2005) reported that five kids, aged 1 week, inoculated with 2 species of *Mycoplasma*. Infected kids showed acute septicaemic clinico-pathological signs with a lethal outcome. The lung lesions were characterized by acute bronchopneumonia and interstitial pneumonia. The haematological data were as follows such as leukopenia (both lymphopenia and neutropenia), an increase in prothrombin time and activated partial thromboplastin time, a decrease in antithrombin III, fibrinogen and thrombocytopenia. A severe diffuse micro-thrombosis was also observed demonstrating the central role of the disseminated intravascular coagulation in *Mycoplasma* infection.

2.5. Diseases caused by Virus

Cutlip et al. (1978) reported that ovine progressive pneumonia (maedi) was prevalent in many major sheep producing areas in the United States. They observed the lesions in the lungs mostly, as multiple lymphoid nodules with increased fibromuscular tissue. The virus was isolated from that lesion

Brown et al. (1991) carried out an immunohistochemical study on lesions of respiratory system caused by Peste des Petits Ruminants (PPR) virus. Pathological changes ranged from mild multifocal bronchiolitis and bronchitis to severe bronchointerstitial pneumonia. Lesions were more severe in antero-ventral lobes than that of caudal lobes. The histological nature of viral progress in the goat lungs had many features in common with the processes of pneumonia in dogs due to canine distemper, or pneumonia in man due to measles virus. Immunohistopathological staining of formalin-fixed, paraffin-embedded respiratory tract tissue was performed using an indirect system with rabbit anti-rinderpest virus serum, biotinylated anti-rabbit antibody, streptavidinalkaline phosphatase, and nitroblue tetrazolium chromogen. They found that staining was sensitive in detecting viral antigen in both lung and trachea of all goats.

They also reported that viral antigen was found in both cytoplasm and nucleus of tracheal, bronchial and bronchiolar epithelial cells, type II pneumocyte, syncytial cells and alveolar macrophages. Finally they concluded that the amount of staining correlated directly with the severity of the inflammatory process.

Ismail and House (1991) identified PPR from goats in Egypt. PPR occurred in a flock of 70 goats (with 32% mortality) in Embaba Giza Province of Egypt in January 1987, and among *Ovis ornata* in a zoo in the same province. Inoculation of surviving goats with rinderpest virus prevented further losses. An isolate of virus ("Egypt 87") was obtained.

Sergany et al. (1992) studied the pathology of PPR in sheep in Egypt. They observed an outbreak of PPR in flock of 10 Egyptian sheep in the faculty of Vet. Medicine, Cairo University, for the first time, in July 1988. They reported that the affected animals showed characteristic clinical signs in the form of fever, erosive stomatitis, profuse diarrhoea, respiratory distress followed by collapse and death. The disease resulted in 75% morbidity and 35% mortality. Postmortem examination revealed erosions in lips, cheeks, lower gums, dorsum of the tongue, hard palate, and in severe cases, in the pharynx and upper third of the oesophagus. They observed congestion in the abomasum and caecum and zebra striping of terminal ileum, spiral colon and rectum. The lungs showed small foci of pneumonia. They found microscopically degeneration, necrosis and desquamation of the superficial necrotic epithelium of upper alimentary tract. They also demonstrated intranuclear inclusion bodies but were not a common feature. The intestine showed congestion of mucosa, mononuclear infiltration and degenerated epithelium, some of them revealed cytoplasmic inclusions. The lungs revealed acute interstitial pneumonia and bronchopneumonia as a secondary complication. They described necrosis and depletion of lymphocytes in the lymph nodes and spleen as well as lymph node involution and reticulo-endothelial hyperplasia.

Sil et al. (1995) reported the outbreaks of PPR in different organized goat farms in Bangladesh and stated that outbreaks were always associated with the introduction of new goats from outside. They observed that 100% of the new goats were infected, while mortality varied from 50% to 90% depending on the managerial practices and environmental conditions. The intensity of infection always found higher during rainy and winter seasons compare to other seasons of the year. They also stated that animals

once recover from PPR remained resistant to the subsequent infections.

Sil et al. (1996) conducted a managemental study of PPR infected goats and developed an antibiotic combined hyperimmune serum therapy (ACHST). In that approach, they used PPR hyperimmune serum (10 ml, 5 log₁₀ PRNT/ ml) and oxytetracycline LA 1 ml/ 10 kg body weight accompanied by other supportive therapies. 100% recovery was obtained during incubation period and prodromal phase of infection. However proper managemental system and environmental stress played an important role in practicing the said therapeutic approach.

Islam et al. (1996) studied the pathology of PPR infection and reported that post-mortem findings of PPR infected animals showed a consolidated lungs and brush paint haemorrhages in heart. Histologically, lungs showed fibrino-purulent pneumonia and the presence of huge numbers of gaint cells. They also reported that there was a severe depletion of lymphocytes in the lymph nodes of PPR infected goats. They also reported that hyperimmune serum raised in rabbit against rinderpest vaccine virus developed clear precipitation in agar gel immunodiffusion.

Jones et al. (1997) described the pulmonary adenomatosis (jaagsiekte) of sheep. The lesions of jaagsiekte consisted of multiple foci of neoplastic alveolar type II cells in acinar and papillary patterns. The result was a pronounced thickening of the alveolar walls and their interstices and partial obliteration of the alveolar spaces by small adenocarcinomas. A certain number of mononuclear cells and lymphocytes spill over into the alveoli and accompanied by a few neutrophils, appeared as exudate in some of the bronchi.

Aliello and Mays (2000) described the progressive pneumonia (Maedi or Marsh's progressive pneumonia) in goats. The microscopic lesions of progressive pneumonia were confined to the lungs and associated lymph nodes. The lungs did not collapse when the thorax was opened and were abnormally firm and heavy. Gray and brown areas of consolidation mottled the lungs. Interstitial pneumonia, perivascular and peribronchial lymphoid hyperplasia, and hypertrophy of smooth muscle were seen throughout the entire lung.

Aruni et al. (2005) worked on the outbreaks of Peste des Petits Ruminants in the pasumpon Muthuramalingam district of Tamil Nadu, India. More than 10 outbreaks occurred in goats among a mixed population of sheep and goats. Clinical signs included purulent oculonasal discharge, severe cough and diarrhoea. Histopathological examination of 48 goats revealed extensive involvement of lungs, lymph nodes, spleen, intestine and liver in descending order of severity. The kids were more susceptible than adults.

2.6. Neoplasms

Khan et al. (1995) studied on systemic mastocytosis in a 4- year-old, female Nubian goat. Clinically, the animal was depressed and had severe macrocytic hypochromic anemia and leukopenia. Postmortem examination revealed neoplastic mast cells invading the heart, lung, liver, spleen, lymph nodes and bone marrow. Eosinophils were frequently admixed with infiltrating cells in all organs. Using routine light microscopy, histochemistry and transmission electron microscopy, metachromatic and periodic acid-schiff-positives granules were identified within the cytoplasm of neoplastic mast cells. Erythrophagocytosis was observed in some neoplastic cells, although its contribution to the anemia was not clear. This report represented the first description of mast cell neoplasia in the goat.

Glavits et al. (2003) studied on pulmonary adenomatosis in a goat. A 3-year -old pregnant goat showed gradually progressive respiratory signs including dyspnoea, tachypnoea, coughing, tachycardia (pulse rate: 100 to 120/min), anorexia and loss of body weight. Pathological examination revealed enlarged lungs that had greyish- white, compact foci with a diameter of 0.5 to 3 cm on the surface and cut sections. The foci protruded over the surface and were frequently confluent. Histological examination showed typical bronchoalveolar adenocarcinomas. Other organs were intact.

2.7. Miscellaneous Disease Conditions

Alibasoglu and Arda (1976) examined 41000 lambs at slaughterhouse and found acute catarrhal bronchopneumonia, necrotic and proliferative bronchitis, nodular lymphocytic peribronchiolitis, interstitial and necrotic pneumonia, cytoplasmic inclusion bodies in bronchial epithelial cells and toxoplasma cyst in pneumonic areas of the lungs.

In another study, they examined 11744 sheep at different slaughterhouses in turkey and found 1023 and 24 positive cases for jaagsiekte and Maedi, respectively.

McGowan *et al.* (1978) observed sub-clinical lesions of enzootic pneumonia in 79.93% of young lambs and reported a high prevalence of pleurisy in sheep over one year age.

Zubaidy and Sokkar (1979) observed histopathological evidence of ovine pulmonary adenomatosis in sheep of Iraq. The lesion was characterized by glandularization of the affected lungs accompanied with metaplastic conditions toward mucin secretion and myxomatous changes.

Moteane *et al.* (1979) tabulated the disease conditions of sheep originating from different parts of Saskatchewan in 1975-76 and 50 sheep submitted for postmortem examination from 13 farms in 1976-77. They noted that the most important causes of mortality were diseases of the digestive and respiratory systems, particularly pulmonary abscessation and acute bronchopneumonia. Annual mortality in adult and feeder sheep in 13 farms was estimated to be 3%. They diagnosed chronic progressive pneumonia (visna-maedi) both pathologically and serologically in a flock.

Rahman and Iyer (1980) studied on pathology of ovine pneumonia. Out of 790 apparently normal slaughtered sheep, 135 showed various lesions. Bacterial pneumonia accounted for 32 cases, viral pneumonia of jaagsiekte for 6, maedi for 2, sheep pox for 2 and giant cell pneumonia for 1 case. Verminous pneumonia was recorded from 35 cases. The other parasitic lesions recognized were granuloma, schistosomiasis, hydatid cyst and trematode.

Ramirez and Pijoan (1980) reported that the annual frequency of pneumonic lesions in the goats and lambs slaughtered in Mexico. They found pneumonia in 10.4% of 8523 goats and 10.1% of 3862 lambs between October 1978 and June 1979. The incidence of the disease was directly proportional to the environmental temperature but was not related to the amount of rainfall.

Rein and Cargill (1981) worked in an abattoir for diseases of feral goats in Australia. They recorded caseous lymphadenitis, pneumonia, cysticercosis, external

parasites and sarcosporidiosis. The pneumonic lesions in 28 (54%) of 518 goats from Ivanhoe, New South Wales and 18 (3.7%) of 485 goats from Northern South Australia were observed. They examined grossly the affected lung tissue and found red and firm. The cut surfaces had a dense and collapsed appearance with mucus partly occluding some bronchioles. Histological lesions were exudative and fibrinous changes involving the alveoli and corresponding bronchioles. The epithelial lining of bronchioles showed hyperplasia upto several layers cellular exudate in the lumen.

Shariraman *et al.* (1982) reported the mortality rate of goats in Andhra Pradesh, India. Such mortality resulted from pneumonia reported to be equal in both sexes.

Ali (1985) examined 52 apparently abnormal lungs of goats collected from various places of Mymensingh, Bangladesh. This investigation revealed varieties of diseases and pathological conditions affection the lungs of goat. Such disorders included dictyocaulosis (3 cases), hydatidosis (4), pulmonary abscess (9), purulent bronchopneumonia (21) nodular lymphocytic peribronchitis (11), and dark-red circular lung lesion (4). The author also found that the respiratory tracts of female goats were more susceptible to the parasitic diseases than the male and the incidence of bronchopneumonia were remarkably high.

Upadhyaya and Rahman (2001) studied the prevalence and pathology of caprine pneumonia in Assam. The authors collected 170 lungs having pneumonic lesion after examination of 1050 goat lungs at Army slaughterhouse, Narengi. The pneumonic lungs were examined microscopically and bacteriologically. The overall incidence of pneumonia was 19.2% and comprised the following types: haemorrhagic (58.8%), fibrinous (48.28%), broncho-pneumonia (32.35%), interstitial pneumonia (6.4%), jaagsiekte (2.35%) and maedi (4.7%). *Pasteurella multocida* was the most common pathogenic bacteria in fibrinous pneumonia whereas *E. coli* was associated with broncho-pneumonia.

Jones *et al.* (2007) described the alveolar pulmonary emphysema of cattle. Microscopically, many alveoli were too large and many had wide openings into each other or into a common space due to rupture of alveolar walls. Some of the walls were slightly thickened hence, inelastic but others were stretched and very thin.



CHAPTER III

MATERIALS AND METHODS

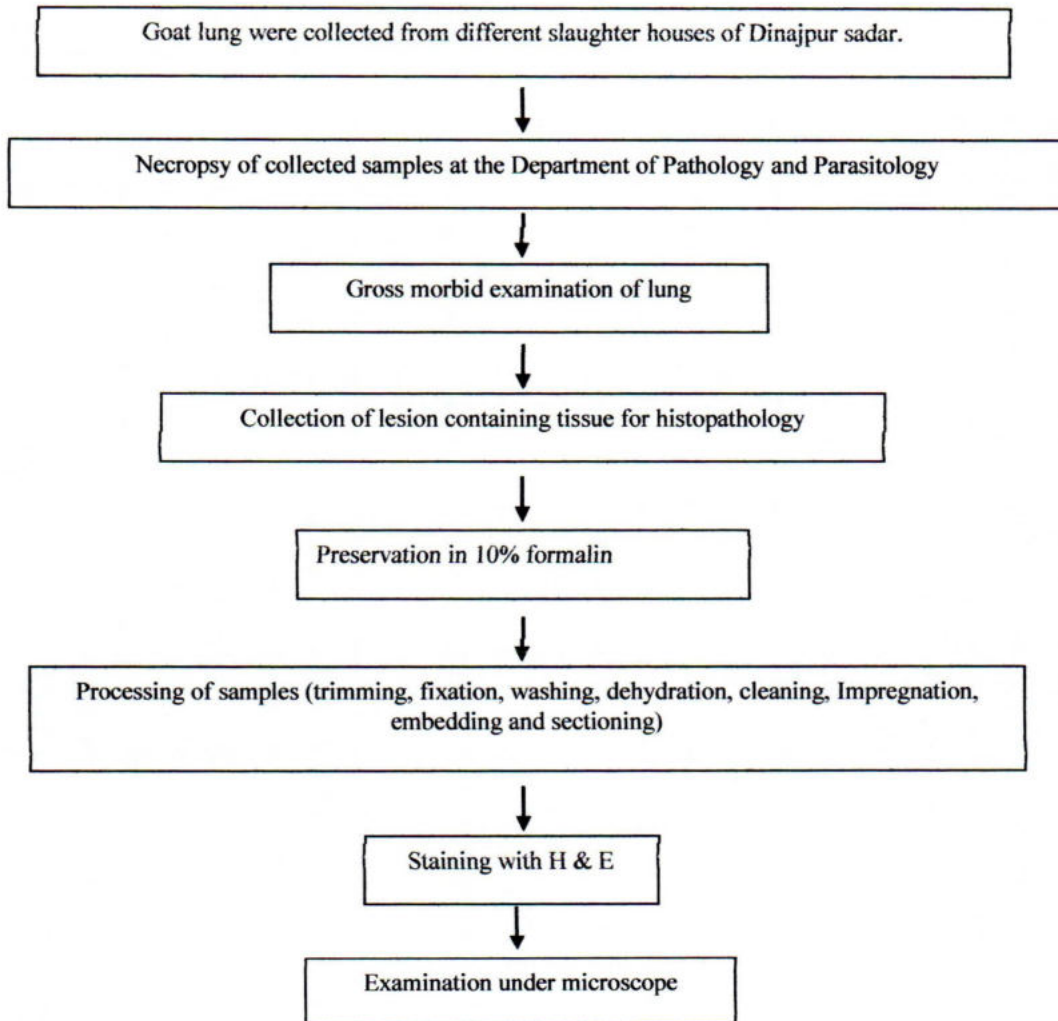
3.1. Experimental samples, areas and duration

In order to identify the lung lesions, a total of 300 slaughtered goats were examined and 24 apparently affected lungs were collected for detailed pathological and microbiological studies. Date of collection, age and sex were recorded. The experimental samples of this study were collected from slaughter house of Bahadur bazar, Suihari bazar, Ramnagar bazar, Gopalganj hat and Birgonj hat of Dinajpur district. The samples were collected with sterile instrument and transferred in the laboratory of the Department of Pathology and Parasitology for necropsy and histopathological examination. The duration of this study was March 2011 to February 2012.

3.2. Cleaning and sterilization of required glassware

Test tubes, glass tubes, glass slides, cover slips, beakers, pipettes, reagent bottles, glass bottle, spirit lamp, measuring cylinders etc. were used in this study. The conical flask, measuring cylinder, beakers, glass slides, cover slip, for the slide preparation of histopathological study and staining of organisms after smear and pipettes, reagent bottle, glass tubes for different biochemical tests. New and previously used glassware were collected and dipped in 2% sodium hypochlorite solution and left there until cleaned. After overnight soaking in a household dishwashing detergent solution, the glassware were cleaned by brushing and washed thoroughly in running tap water and rinsed three times in distilled water. The cleaned glasswares were then dried on a bench at room temperature or in an oven at 50-70°C

EXPERIMENTAL DESIGN



Flow diagram of the experiment

3.3. Histopathology

Formalin fixed tissue samples were processed and stained as per standard method (Luna, 1968).

3.3.1. Materials required for histopathology

- Samples (lungs)

- 10% formalin
- Chloroform
- Paraffin
- Alcohol
- Tape water
- Xylene
- Hematoxylin and Eosin stain
- Distilled water
- Clean slides
- Cover slips
- Mounting media (DPX).
- Microscope
- Microtome
- Water bath

3.3.2. Processing of tissue for histopathology

1. Collection of tissue and Processing

During tissue collection the following point were taken into consideration-

The tissues were collected in conditions as fresh as possible. Normal and diseased tissues were collected side by side. The thickness of the tissues were as less as possible (5mm approximately). The tissues (lungs) were collected from the goats in the Histopathology Laboratory of the Department of Pathology and Parasitology, HSTU, Dinajpur.

2. Fixation: 10% formalin was added in the plastic container (10 folds of the tissue size and weight) and fixed for 3-5 days.

3. Washing: The tissues were trimmed into a thin section and washed over night in running tap water to remove formalin.

4. Dehydration: The tissues were dehydrated by ascending ethanol series to prevent shrinkage of cells as per following schedule.

- ❖ 50% alcohol – one hour
- ❖ 70% alcohol – one hour
- ❖ 80% alcohol – one hour
- ❖ 95% alcohol – one hour
- ❖ Absolute alcohol – three changes (one hour for each changes.)

5. Cleaning: the tissues were cleaned in chloroform for 3 hours to remove ethanol (1 and half hr in each, two changes).

6. Impregnation: Impregnation was done in melted paraffin (56- 60°C) for 3 hours.

7. Embedding: Paraffin blocks containing tissue pieces were made using templates and molten paraffin

8. Sectioning: Then the tissues were sectioned with a microtome at 5-6µm thickness. The sections were allowed to spread on luke warm water bath (40-45 °C) and taken on a glass slide. A small amount of gelatin was added to the water bath for better adhesion of the section to the slide. The slides containing sections were air dried and stored in cool place until staining.

3.3.3. Routine Hematoxylin and Eosin staining procedure

3.3.3.1. Preparation of Ehrlich's Hematoxylin solution

Hematoxylin crystals	4.0 g
Alcohol, 95%	200.0 ml
Ammonium or potassium alum	6.0 g
Distilled water	200.0 ml
Glycerine	200.0 ml
Glacial acetic acid	20.0 ml

Hematoxylin was dissolved in the alcohol and the alum was dissolved in distilled water and mixed thoroughly. After these were in complete solution the glycerin and acetic acid were added.

3.3.3.2. Preparation of eosin solution

1% stock alcoholic eosin

Eosin Y, water soluble	1 g
Distilled water	20 ml
95% alcohol	80 ml

Eosin was dissolved in water and then 80 ml of 95% alcohol was added.

Working eosin solution

Eosin stock solution	1 part
Alcohol, 80%	3 parts

0.5ml of glacial acetic acid was added to 100 ml of working eosin solution just before use.

3.4. Staining protocol

The sectioned tissues were stained as described bellow:

- ❖ The sectioned tissues were deparaffinized in three changes of xylene (three minutes in each)
- ❖ Then the sectioned tissues were rehydrated through descending grades of alcohol as per following schedule.
 - Absolute alcohol – three changes (three minutes for each)
 - 95% alcohol - two minutes
 - 80% alcohol - two minutes
 - 70% alcohol - two minutes
 - Dipping with distilled water for 10 minutes.
- ❖ The tissues were stained with Harris hematoxylin for 2-10 minutes.
- ❖ Washed in running tap water for 10-15 minutes.
- ❖ Then the tissues were dipped in ammonia water (few dips).
- ❖ Stained with eosin for one minute.
- ❖ Differentiated and dehydrated in ascending grade of alcohol.
 - 95% alcohol – three changes (2-4 dips for each.)
 - Absolute alcohol – three changes (2-3 minutes for each)
- ❖ *Cleaned in xylene: three changes (five minutes each).*
- ❖ Tissues were mounted with cover slip by using DPX
- ❖ The slides were dried at room temperature and examined under a low (10X) and high (40X, 100X) power objectives.

3.5. Photography

All the characteristic pathologic changes were subjected to gross photographs and the characteristic microphotographs were taken by personal Sony camera in the *Department of Pathology and Parasitology, HSTU.*

CHAPTER IV

RESULTS

In order to detect the prevalence of lung lesions in goats at some slaughterhouses of Dinajpur during the period from March 2011 to February 2012, a total of 300 goats were examined and of them 24 lungs were found to be apparently abnormal. Therefore, the prevalence of lungs lesions in goats was recorded 8%. The occurrence of different lungs diseases or lesions diagnosed during this investigation was shown in the Table- 1. The Table-1 comprised of the following types lung lesions or diseases: Purulent pneumonia 1.33%, Interstitial pneumonia 1.00%, Pulmonary hemorrhage 1.67%, Fibrinous pneumonia 0.66%, Emphysema 1.00%, Hydatidosis 0.33% and No major lesions 2.00%, respectively.

The goats of both sexes were slaughtered at the slaughterhouse but the number of females was higher than males and the occurrence of lung lesions were also higher in females (62.5%) than males (37.5%). The number of male and female goats affected with different lung lesions or diseases were shown in the Table- 2. In both sexes, Pulmonary hemorrhage, Purulent pneumonia and Emphysema were of high occurrence.

For convenience of description, the different lung lesions or diseases were described under the following headings and sub-headings depending on the extent of affected areas and nature of exudation and inflammatory cells.

• LUNG LESIONS OR DISEASES

1. Purulent pneumonia
2. Interstitial pneumonia
3. Pulmonary hemorrhage
4. Fibrinous pneumonia
5. Emphysema
6. Hydatidosis
7. No major lesions

LUNG LESIONS OR DISEASES

4.1 Purulent pneumonia

The prevalence of purulent bronchopneumonia was recorded 1.33%.

Gross lesions

There were numerous minute white foci on the parietal surface of left and right apical lobes & left diaphragmatic lobe and most part of the visceral surface. Grossly, the lung was hard in consistency and consolidation of diaphragmatic lobes, apical lobes, cardiac lobes and even the whole lung involved (Figs. 1).

Microscopic lesions

Microscopic lesions were characterized by the presence of inflammatory cells consisted of mainly neutrophils within the lumen of bronchiole. Adjacent to the bronchioles, there were focal infiltration of large number of neutrophils and few lymphocytes. On the other parts of the lung tissue, there were presence of plasma cells, macrophages and lymphocytes (Fig.2).

4.2 Interstitial Pneumonia

The prevalence of interstitial pneumonia was recorded 1.00%.

Gross lesions

The whole lung was reddish in color. There was presence of small dark-red spot on the left apical and diaphragmatic lobes and hard on palpation (Fig.3).

Microscopic lesions

The inter-alveolar septa were thickened due to accumulation of inflammatory cells and proliferation of fibrous connective tissue (Fig.4). There was presence of exudates within the alveoli. Hemorrhage in the alveoli and congestion of blood vessels were also present in some foci.

4.3 Pulmonary hemorrhage

The prevalence of hemorrhagic pneumonia was recorded 1.67%.

Gross lesions

The lungs showed the presence of dark-red circular area, measuring 2 to 4 cm in diameter. It was found on parietal surface of left apical, left and right diaphragmatic lobes. On incision, dark-red colored clotted mass was observed. The left apical, cardiac and diaphragmatic lobes were heavily congested. (Fig.5)

Microscopic lesions

There was presence of excessive hemorrhage within the Alveoli and inter-alveolar septa associated with leukocytic infiltration. Hemorrhage and leukocytic infiltration were also found in the lumen of the bronchus. The wall of the bronchus also showed the inflammatory changes and mild necrosis in the mucosal layer. In some places only pink color edema fluid were present in the lumen of the alveoli. (Figs.6)

4.4 Fibrinous pneumonia

The prevalence of fibrinous pneumonia was recorded 0.66%.

Gross lesions

A sheet of yellow fibrin was loosely adhered to the pleural surface and between the apical lobes of the lungs. These lobes were firm, reddish in color and consolidation of the left apical lobe was observed. Right diaphragmatic lobe showed slightly emphysematous. (Fig-3)

Microscopic lesions

There was presence of network of fibrin associated with a few reactive cells (Fig.7). In addition, reactive cells were also found in the lumen of bronchiole and some in alveoli and inter-alveolar septa. There was diffuse alveolar necrosis, edema of inter-alveolar septa, and sloughing of bronchial mucosa.

4.5 Emphysema of lungs

The prevalence of emphysema of lung was recorded 1.00%.

Gross lesions

The left side of the lung was reddish in colour while the right side was pale in colour, dry with gray colour elevated areas and was easily compressed by the finger. There was also presence of slight congestion in the apical lobes (Fig.8).

4.6 Hydatidosis

The prevalence of hydatidosis was recorded 0.33%.

Gross lesions:

The cysts were found both at the parietal surfaces of left and right diaphragmatic and apical lobes (Fig.9) but not in the cardiac lobe. The maximum numbers of cysts in a lung were three and the minimum being one. The size of the cysts ranged from 2 cm. in diameter and 2cm wide. Most of the cysts were Situated superficially just beneath the pleura. The wall of cyst was whitish in colour and the cystic fluid was clear and its volume ranged from 1 ml to 15 ml. numerous brood capsules originating from the inner most laver of the cyst were observed to float as 'hydatid sand' in the cystic fluid.

Table-1: The occurrence of different lung diseases or lesions in goats

Sl. No.	Lung diseases/ lesions	Total no. of goat examined	No. of affected lung	No. of affection	Percentage (%) of affection
1.	Purulent pneumonia	300	24	4	1.33
2.	Interstitial pneumonia			3	1.00
3.	Pulmonary hemorrhage			5	1.67
4.	Fibrinous pneumonia			2	0.66
5.	Emphysema			3	1.00
6.	Hydatidosis			1	0.33
7.	<i>No major lesions</i>			6	2.00

Table-2: The proportional occurrences of different lungs diseases or lesions in goats in relation to sex.

Sl. No.	Lung diseases/ lesions	Male n = 9 (37.5%)		Female n = 15 (62.5%)	
		No. of affected	% of affected	No. of affected	% of affected
1.	Purulent pneumonia	2	22.22	2	13.33
2.	Interstitial pneumonia	1	11.11	2	13.33
3.	Pulmonary hemorrhage	2	22.22	3	20.00
4.	Fibrinous pneumonia	1	11.11	1	6.67
5.	Emphysema	1	11.11	2	13.33
6.	Hydatidosis	0	0.00	1	6.67
7.	No major lesions	2	22.22	4	26.66

n = Number of animals.

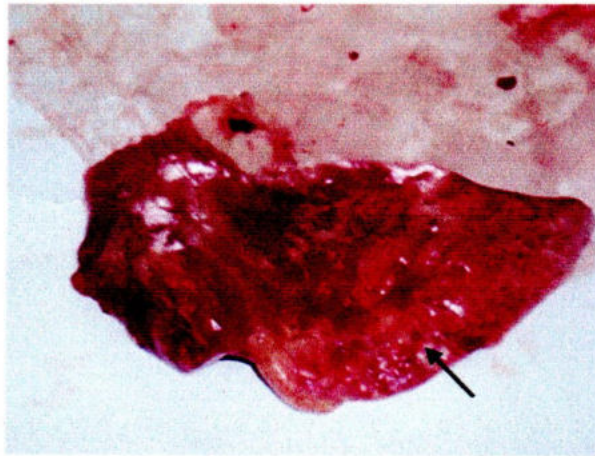


Fig.1: Picture of lung collected from goat at Bahadur bazar slaughter house. Grossly pus was found in lung (Blackarrow).

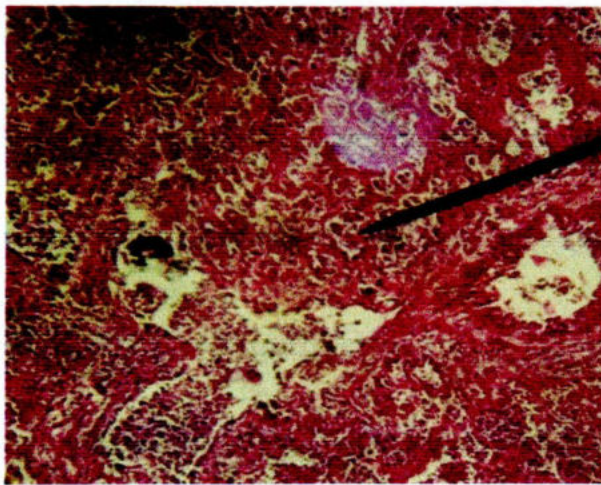


Fig.2: Slide of goat lung showing infiltration of inflammatory cells mainly and few neutrophils within the lumen of bronchiole detected under a high power objective (100X).

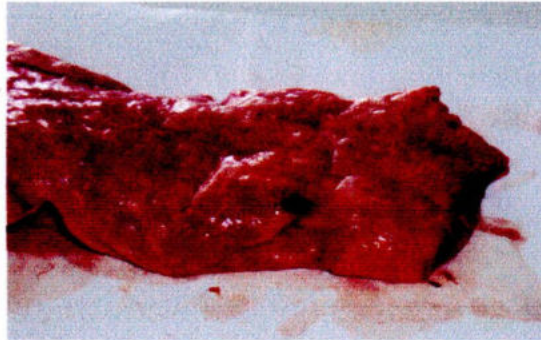

Fig.3: Picture of lung collected from goat at Suihari slaughter house. Grossly pneumonia was found in lung.

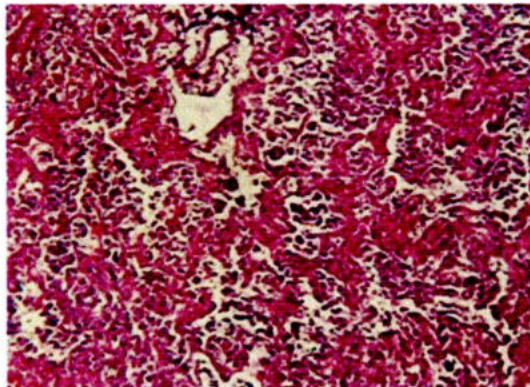


Fig.4: Slide of goat lung showing infiltration of inflammatory cells in the inter-alveolar septa were detected under a high power objective (100X).

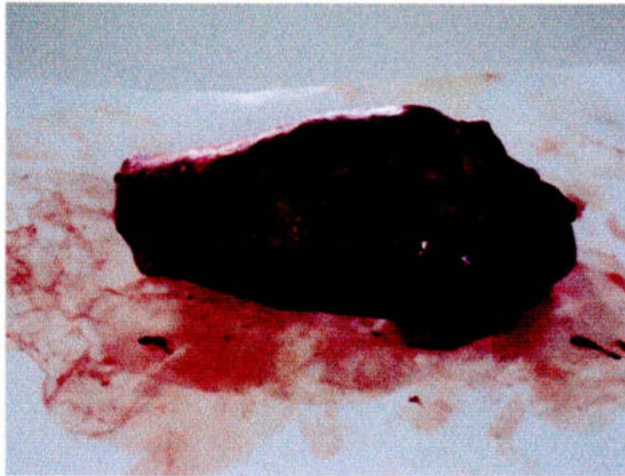


Fig.5: Picture of lung collected from goat at Ramnagar slaughter house. Grossly haemorrhage were found in lung.

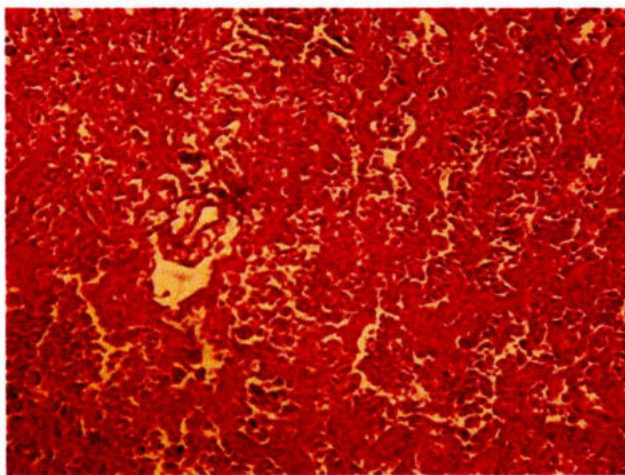


Fig.6: Slide of goat lung showing inflammatory changes in the wall of bronchus detected under a high power objective (100X).

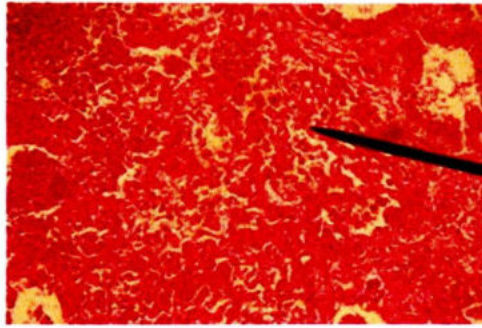


Fig.7: Slide of goat lung showing network of fibrin associated with a few reactive cells detected under a high power objective (100X).

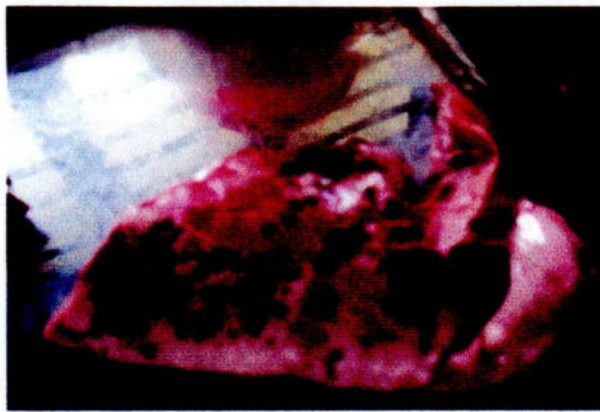


Fig.8: Picture of lung collected from goat at Suihari slaughter house. Grossly emphysema was found in lung.

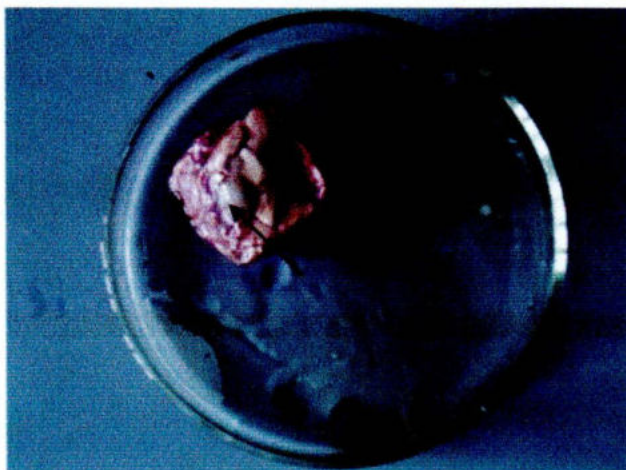


Fig.9: Picture of lung collected from goat at Birgonj slaughter house. Grossly hydatid cyst was found in lung (Black arrow).

CHAPTER V

DISCUSSION

Respiratory diseases, one of the major constraints in the development of goat farms in Bangladesh. So, for the development of goat population, emphasis should be given to check the respiratory infections. The prevalence of disease in a particular area depends on various factors like geo-climatic condition, biological barriers, immunization status, social awareness etc. So, the present investigation was conducted on slaughtered goats in Dinajpur district to categorize different lung lesions.

In this investigation the prevalence of lung affections was recorded 8% in goats which was less than those reported by Ramirez and Pijoan (1980) from Mexico, Hein and Cargill (1981) from New South Wales, Upadhyana and Rahman (1993) from Assam (Army slaughterhouse) and Jha and Beier (1996) from eastern hills of Nepal (The analysis of goat postmortem records of pakhribas Agricultural Centre) where they reported the prevalence 14.40%, 54%, 19.2% and 31.6%, respectively. This variation in prevalence might be due to climatic conditions, geographical distribution, species variation, population size etc. This might also be due to the difference in environmental temperature as Ramirez and Pijoan (1980) reported that the incidence of the respiratory diseases was directly proportional to the environmental temperature but not related to rainfall. But this prevalence (8%) was more than those reported by Ali (1983), from Mymensingh, Bangladesh where he reported 2.17%. Ali (1983) collected 52 apparently abnormal lung out of 2400 goats during the period of February-September, 1982. In the present study a total of 24 abnormal lungs were collected out of 300 slaughtered goats during the period from March 2011- February 2012. So the variation in the prevalence in the present study than the previous study might be due to sample size.

The highest prevalence of this investigation was Pulmonary haemorrhage (1.67%). Following inhalation of hemorrhagic bacteria into the lung there is an accumulation of neutrophils, which when destroyed by leukotoxin result in the release of proteolytic enzymes, oxidant products and basic proteins degrade cellular membranes, increasing capillary permeability which result in fluid accumulation in the interstitium of alveolar wall. However, the organism can induce severe pulmonary damage through both neutrophil and neutrophil independent mechanisms. The organism can also cause rapid

cytolysis of platelets. The lipopolysaccharide of bacteria is capable of causing direct injury to endothelial cells of pulmonary artery (Radostits *et al.*, 1994). In addition, Scholes and Kelly (1997) observed that there was procoagulant effect of bacterial endotoxin on vascular endothelium in goats. In this investigation, except thrombus in vascular lumen, extensive hemorrhage, edema and inflammation were recorded in Pulmonary hemorrhage which were consistent with the other findings (Radostits *et al.*, 1994; Scholes, *et al.*, 1997).

The second highest prevalence was Purulent pneumonia. Four lungs, out of 24 apparently abnormal lungs were affected with purulent bronchopneumonia. Sarker and Bhattacharyya (1975) reported that 30 goats died of Purulent pneumonia out of 98 cases. Dadhich and Sharma (1998) from Rajasthan reported the prevalence of purulent pneumonia in goats 1.58% of the 2217 examined lungs, whereas, in this study the value was 1.33% of the 300 examined lungs. This variation is due to the sample size.

The prevalence of emphysema of lung was 1.00%. The proposed mechanism for development of lung emphysema (i) primary deficiency in the strength of the supporting tissues which are thus unable to support the alveolar walls during coughing or exertion (ii) the other hypothesis is that chronic bronchial spasm due to allergy cause obstruction of the air passages but air still enters the alveoli through the communications between them. This air accumulates causing over distension and finally ruptures of the alveoli (Radostits, 1994).

The prevalence of hydatidosis reported in lung by Islam (1981) from Bangladesh, Verma and Ahluwalia (1991) from Uttar Pradesh, India, Hussain *et al.*, (1992) from Pakistan, Das and Sreekrishan (1998) from Pondicherry, India, and Sobein *et al.*, (1998) from Gassim abattoir, Saudi-Arabia were 32.03%, 43.0%, 63.07%, 32.0% and 8.29% respectively. The prevalence of hydatidosis in the present study was recorded 0.33%. It might be due to the fact that the work of Islam (1981) was done in different localities of Bangladesh whereas; the present work was performed only in Dinajpur district. Over all, hydatidosis rate in females was higher than in males which were similar to those reported by Hussain *et al.* (1992).

The other lesions in this investigation recorded as Fibrinous pneumonia (0.66%) and Interstitial pneumonia (1.00%) which was less than those reported by Upadhyaya and Rahman (1993) and there were Fibrinous lesion (48.28%), and Interstitial pneumonia (6.4%). This variation may also be due to climatic conditions, geographical distribution and breed variations. However, the gross and histopathological lesions were almost similar as reported by other authors (Jones *et al.*, 1997, Upadhyaya and Rahman, 1993).

CHAPTER VI

SUMMARY AND CONCLUSION

A total of 300 slaughtered goats were examined to detect the prevalence of lung lesions or diseases from the slaughterhouses of Bahadur bazar, Suihari bazar, Ramnagar bazar, Gopalganj hat and Birgonj hat of Dinajpur district during the period From March 2011 to February 2012.

The investigation revealed a total of seven (7) types of lung diseases or lesions. Out of 300 slaughtered goats, histopathologically the prevalence of lung diseases or lesions were Purulent pneumonia 1.33%, Interstitial pneumonia 1.00%, Pulmonary hemorrhage 1.67%, Fibrinous pneumonia 0.66%, Emphysema 1.00%, Hydatidosis 0.33% and No major lesions 2.00%, respectively and the total percentage of lung affections was 8%.

However, the overall prevalence of lung lesions or diseases of goats were found to be higher in females than males. Both gross and histopathological lesions of above or pathological conditions were described.

On the basis of findings of this study, the following conclusions were drawn:

1. The total occurrence of lung lesions or diseases were 8%. So, emphasis should be given to check the respiratory affections for the development of profitable goat farms.
2. The lungs of goats were less susceptible to parasitic diseases. Only one lung was found to be affected with hydatidosis but other lung worms were not found.
3. The highest prevalence was Pulmonary hemorrhage 1.67% and the second highest prevalence was Purulent pneumonia (1.33%).
4. In the present study, the highest prevalence of lung lesions or diseases of goat were higher in females (62.5%) than males (37.5%).

This study on caprine lung will focus the different diseases and lesions. In maximum cases, the causative agents were not identified from the lung lesions. In near

future the attempts should be taken to identify the causative agents. Moreover, meat inspection should be performed by the Veterinarian to save the people from zoonotic diseases, like hydatidosis. The findings of this investigation will help the Veterinarian for the treatment and control of diseases of caprine lung.

REFERENCES

- Aiello, S. E. and Mays, A. [ed.] (2009,a). *The Merck Veterinary Manual*. 8th edition, Merck and co., Inc., U. S. A., pp- 1110- 1111.
- Aiello, S. E. and Mays, A. [ed.] (2009,b). *The Merck Veterinary Manual*. 8th edition, Merck and co., Inc., U. S. A., pp- 1111- 1112.
- Ali M. R. (1983). Studies on incidence and pathology of diseases affecting, the respiratory tract of goat. M. Sc. Thesis, Dept. of Pathology, Faculty of Veterinary Science, BAU, Mymensingh.
- Alibasoglu, M. and Arda, M. (1976). *Study of pulmonary adenomatosis in sheep in Turkey, with special reference to the pathology and aetiology*. Vet. Bull. 46(6) : 3218.
- Almeida, P. F. de., Alves, F. S. F., Santos, L. de. F., Rosa, J. S. and DeAlmeida, P. F. (1986). Survey of bacterial agents associated with respiratory diseases of goats in North Eastern Brazil. *Revista-de- Microbiologia*. 17:3, 213-215.
- Anon,(1988). Five years Development of Fisheries and Livestock, 1981-82 and 1985-86. Ministry of Fisheries and Livestock, Government of People's Republic of Bangladesh, Dhaka.
- Anwar, A. H., Haq, A. U., Gill, S. A. and Chaudhury. A. H. (1993). Prevalence and fertility ratio of hydatid cyst in slaughtered sheep and goat at Faisalabad. *Pakistan Veterinary Journal*, 13:79-81.
- Aruni, A. W., Lalitha, P. S., Mohan, A. C., Chiltravelu, P. and Anbumani, S. P. (1998). Histopathological study of a natural outbreak of pesti-des- petits ruminants in goats of Tamillnadu. *Small Ruminant Research*. 28 (3): 233-240.
- Ashraf, M., Khan, M. Z. and Chishti, M. A. (1986). Incidence and pathology of lungs affected with tuberculosis and hydatidosis in sheep and goats. *Pakistan Veterinary Journal*. 6 (3) : 119-121.

- Brown, C. C., Mariner, J. C. and Orlander, J. (1991). An Immunohistochemical study of the pneumonia caused by PPR virus. *Vet. Path.* 28 (2): 166-170.
- Carter, G. R. and Chengappa, M. M. (1993). *Microbial Diseases. A Veterinarian's Guide to Laboratory Diagnosis*. 1st edition, Iowa state University press, Ames, Iowa, U. S. A., pp. 172.
- Cutlip, R. C., Jackson, T. A. and Laird, G. A. (1978). *Prevalence of ovine progressive pneumonia in a sampling of cull sheep from Western and Mid-Western United States*. *Vet. Bull.* 48 (9): 5379.
- Dada, B. J. O., Adegboye, D. S. and Mohamed. A. N. (1979). The epidemiology of echinococcus infection in kaduna state, Nigeria. *Helm. Abstr.* 48: 4929.
- Dadhich, H. and sharma, G. D. (1996,a). Pulmonary schistosomiasis in goats in Rajasthan. *Indian Veterinary Journal.* 73 (6): 677- 678.
- Dadhich, H. and sharma, G. D. (1996,b). Incidence and pathology of mycotic pneumonia in goats of Rajasthan. *Indian Veterinary Journal.* 73 (6): 679-680.
- Dadhich, H. and sharma, G. D. (1998). Pathological observations of purulent pneumonia in goats. *Indian Veterinary Journal.* 75 (10) : 937-938.
- Das, S. S. and Sreekrishnan, R. (1998). Prevalence of hydatidosis in sheep and goats in Pandicherry. *Journal of Veterinary Parasitology.* 12 (2): 45- 146.
- EL- Manakhly, E. M. (1995). The pathology of an outbreak of mycoplasmal infection among adult goats. *Egyptian Journal of Comparative Pathology and Clinical Pathology.* 8 (1): 9-15.
- FAO, quarterly bulletin of statistics (1999). Food and Agricultural Organization of the United Nations. Rome, Vol. 12, pp. 148.
- Gabriele, F., Concheda, M., Ecça, A. R., Palmas, C., Seu, V. and Bortoletti, G. (1998). Livestock hydatidosis in Sardinia. *Igiene Modcrim.* 110 (1): 13-22.

- Gajendragad, M. R., Prabhudas, K. and Yadav, M. P. (1986). A case of sporotrichosis in a goat. *Indian Veterinary Journal*. 63 (8): 685.
- Gezon, H. M., Bither, H. D., Gibbs, H. C., Acker, E. J., Hanson, L. A. and Thompson, J. K. (1988). Identification and control of paratuberculosis in a large goat herd. *American Journal of Veterinary Research*. 49 (11) 1817-1823.
- Glavits, R., Molnar, T., Palfi, V. and Tenk, M. (1996). *Pulmonary adenomatosis in a goat*. *Magyar- Allatorvosok -Lapja*. 51 (10): 582-584.
- Guler, L., Baysal, T., Gunduz, K., Ergams, O., Kaya, O. and Orhan, G. (1996). Biotyping and serotyping of *Pasteurella haemolytica* strains isolated from sheep and goats. *Veterinarium*. 7 (1-2) 5-12.
- Gutierrez, C., Rodriguez, J. L., Montoya, J. A. and Fernandez A. (1999). Clinico-pathological and haematological findings in goat kids experimentally infected simultaneously with *Mycoplasma mycoides* sub sp. *capri* and Small Ruminant Research . 31 (3): 187-192.
- Hayashidani, H., Honda, E., Nakamura, T., Mori, Y., Sawada, T. and Ogawa, M. (1988). Outbreak of pneumonia caused by *Pasteurella haemolytica* infection in Shiba goats in Japan. *Japanese Journal of Veterinary Science*. 50 (4): 960-962.
- Hein, W. R. and Cargill, C. F. (1981). An abattoir survey of Diseases of Feral goats. *Australian Vet. Jour*. 57: 498-500.
- Himonas, C., Antoniadou, S. K. and Papadopoulos, E. (1994). Hydatidosis of food animals in Greece: Prevalence of cysts containing viable protoscoleces. *Journal of Helminthology*. 68 (4):311-313.
- Hussain . A., Maqbool, A., Hussain, S., Athar. M., Shakoora. A. and Amin, M. K. (1992). Studies on prevalence and organ specificity of hydatidosis in ruminants slaughtered at Karachi and Faisalabad abattoir, Pakistan. *Indian Journal of Dairy science*. 45 (9): 454-456.

- Iqbal, Z., Hayat, C.S., Hayat, B. and Khan, M. N. (1987). Incidence of hydatidosis in Teddy goats slaughtered at Faisalabad abattoir. *Helm. Abstr.* 56:273.
- Islam, M. R., Shamsuddin, M., Das, P.M., and Dewan, M. L. (1996). Peste des Petits Ruminants: a high contagious virus disease affecting goats in Bangladesh. Presented at the 14th Annual conference of Bangladesh Society of Microbiology.
- Islam, S. A. W. M. (1981). *Hydatid disease in goats in Bangladesh, Animal Disease Occurrence.* 2 (1): 239.
- Islam, Z. (1987). Study on the seasonal incidence of abomasal helminths of goats in savar Upazilla, Dhaka. M. Sc. Thesis, Department of Parasitology, Faculty of Veterinary Science, BAU, Mymensingh.
- Ismail. I. M. and House, J. (1991). Evidence and identification of PPR from goats in Egypt. *Vet. Bull.* 61 (1). 30.
- Jarjees, M. T., Hassan, A. A. and Al- sanjary, R. A. (1998). Observations on the prevalence of hydatidosis in slaughtered animals at Mosul abattoir. *Iraqi Journal of Veterinary Science.* 11 (1): 57-60.
- Jha, V. C. and Beier, T. (1996). *Respiratory diseases, with special reference to mycoplasmosis in goats in the eastern hills of Nepal.* *Bull. Vet. Sc. and A. H. Nepal.* 24: 71-74.
- Jones, T. C., Hunt, R. D. and King, N. W. (1997,a). *Veterinary Pathology.* 6th edition, Williams and wilkins, pp. 345.
- Jones, T. C., Hunt, R. D. and King, N. W. (1997,b). *Veterinary Pathology.* 6th edition, Williams and wilkins, pp. 968.
- Jubb, K. V. F., Kennedy, P. C. -and Palmer, N. (1993). *Pathology of Domestic Animals.* 4th edition, Vol. 2, Academic press, Inc., pp. 638.
- Kaliner, G. and Macowan, K. J. (1977). The pathology of experimental and natural contagious caprine pleuro- pneumonia in kenya. *Vet. Bull.* 47:1393.

- Kanwar, N. S., Paliwal, O. P., Ram, K., Kumar, A. A. and Kumar, R. (1998). Pneumonic pasteurellosis in goats. *Indian Journal of Comparative Microbiology, Immunology and Infectious Diseases*. 19:2, 99-101.
- Kapur, M. P., Sadana, J. R., Kalra, D. S. and Chauhan, H. V. S. (1976). Some observations on the causes of lamb and kid mortality at the Haryana Agricultural University, Hissar. *Vet. Bull.* 46: 1775.
- Khan, K. N. M., Sagartz, J. E., koening, G. and Tanaka, K. (1995). Systemic mastocytosis in a goat. *Vet. Pathol.* 32: 719-721.
- Livingston, C.W. Jr. (1975). *Mycoplasma associated with pneumonia in sheep*. *Vet. Bull.* 45(7): 3716.
- Lorenzini, R. and Ruggieri, A. (1987). Distribution of echinococcosis/ hydatidosis in Italy. *Journal of Helminthology*. 61(3): 261-267.
- Luna, L. G. (1968). *Manual of Histologic staining methods of the Armed Forces institute of Pathology*. 3rd edition, McGraw Hill Book Co. New York.
- Masduzzaman, MD. (1995). *Pathological conditions encountered in animal carcasses in abattoirs*. M. Sc. Thesis, Dept. of Pathology, Faculty of Veterinary Science, BAU, Mymensingh.
- Matthews, J. G. (1999). *Diseases of the Goat*. 2nd edition, blackwell Science, pp. 258.
- McGowan, B., Thorley, D. C., McSporran, K. D. and Pfeffep, A. T. (1978). Enzootic pneumonia-pleurisy complex in sheep and lambs. *New-Zealand Vet. Jour.* 26 (7): 169-172.
- Mia, N. H. and Kibria (1993). *A study of livestock for second plan*. Planning commission, Dhaka.
- Midwinter, A. C., Clarke, .I. K. and Alley, M. R. (1986) . *Pasteurella haemolytica* serotypes from pneumonic goat lungs. *Vet. Bull.* 56: 5022.

- Moteane, M., Middleton, D. M. and Polley, L. R. (1979). A survey of disease conditions in adult and feeder sheep in Saskatchewan. *Vet. Bull.* 49 (7): 4018.
- Oge, H., Gicik, Y., Kalinbacak, F. and Yildiz, K. (1998). The prevalence of some metacestodes (Hydatid cyst, *Cysticercus tenuicollis*, *Cysticercus bovis*) in sheep, goat and cattle slaughtered in Ankara province. *Veteriner- Fakultesi- Dergisi- Ankara- Universitesi.* 45 (1):123-130.
- Ojo, M. O. (1976). Caprine pneumonia in Nigeria: epidemiology and bacterial flora of normal and diseased respiratory tracts. *Vet. Bull.* 46 (10): 5901.
- Oros, J. Fernandez, A., Ramirez, A. S., Rodriguez, F., Rodriguez, J. L. and Poveda, J. B. (1997). Microbiological and histopathological study of lungs from a flock with a history of goat pleuropneumonia. *Medicina Veterinaria.* 14 (2): 91-92.
- Paul, L., Cotofan, O., Minascurta, C. and Pop, T. (1978). Lung lesion in parasitic bronchopneumonia in sheep. *Vet. Bull.* 48(2): 922.
- Petsaga, T., Simperi, V. and Sarris, K. (1997). Mycoplasmosis of sheep and goats in northern Greece. *Veterinarski-Glasnik.* 51 (1-2): 49:53.
- Pillai, K. J., Rao, P. L. N. and Rao, K. S. (1986). A study on the prevalence of livdatidosis in sheep and goats at Tiripati municipal slaughter house. *Indian J. publ. health.* 30 (3): 160-165.
- Radostits, O. M., Blood, D. C. and Gay, C. C. [ed.] (1994). *Veterinary Medicine. A text book of the Diseases of Cattle, Sheep, Pigs, Goats and Horses.* 8th edition, *Billiere Tindall.*
- Rahaman, A., Ahmed, M. U. and Mia, A. S. (1975). Diseases of goats diagnosed in slaughter house in Bangladesh. *Tropical Animal Health production.* 7(3): 164.
- Rahman, A., Ahmed, M. U. and Mia, A. S. (1976). *Studies oil the diseases of goats in Bangladesh.* Mortality of goats under farm and rural conditions. *Trop. Amin. Prod.* 8 (2): 90.

- Rahman, T. and Iyer, P. K. R. (1980). Studies on pathology of ovine pneumonia. Vet. Bull. 50 (5):2923.
- Ramirez, R. and Pijoan, C. (1980). Annual frequency of pneumonic lesions among, the goats and lambs slaughtered in Mexico. Vet. Bull. 50 (9) :5881.
- Ray, D. K., Negri, S. K. and Srivastava, P. S. (1978). Note on occurrence of inetacestodiasis in goats in Tarai of Uttar prodesh. Helm. Abstr. 47(10): 4470.
- Rodriguez, J. L., Poveda, J. B., Oros, J., Herraiez, P., Sierra, M. A. and Fernandez, A. (1995). High mortality in goats associated with the isolation of a strain of *Mycoplasma mycoides sub sp. mycoides* (large colony Type). Journal of Veterinary Medicine. 42 (10): 587-593.
- Romboli, B., Pellegrini, N. and Braca, G. (1975). *Cysticercus tenuicollis* infection in the lungs of lambs: pathology and histopathology. Vet. Bull. 45 (6):3214.
- Rushton, B., Sharp, J. M., Gillmour, N. J. L. and Thompson, D. A. (1979). Pathology of an experimental infection of specific pathogen-free lambs with parainfluenza virus type 3 and *Pasteurella haemolytica*. J. Comp. Path. 89:321-329.
- Sadana. J. R., Purohit, V. D. and Kalra, D. S. (1980). Incidence and pathology of verminous pneumonia in sheep and goats. Vet. Bull. 50 (9) 5846.
- Sarker, P. and Battacharya, H. M. (1975). Caprine pneumonia caused by *Corynebacterium ovis*. Vet. Bull. 45 (11) :6113.
- Scholes. S.F. E. and Kelly, D. F. (1997). Pulmonary venous thrombosis in caprine pasteurella pneumonia. Journal of Comparative pathology. 116 (4):415-418.
- Sergany, M. A., Reda, I. M., Sakr, E. E. A. and Abourowash. A. A. (1992). Pathology of PPR in sheep in Egypt. Jour. Com. Path. Clin. Path, 5(1): 25-39.
- Radostits, O. M., Blood, D. C. and Gay, C. C. [ed.] (1994). Veterina Medicine. A text book of the Diseases of Cattle, Sheep, Pigs, Goats and Horses. 8th edition, Billiere Tindall.

- Rahaman, A., Ahmed, M. U. and Mia, A. S. (1975). Diseases of goats diagnosed in Bangladesh. *Tropical Animal Health production* 7(3): 164.
- Rahman, A., Ahmed, M. U. and Mia, A. S. (1976). Studies on the diseases of goats in Bangladesh. Mortality of goats under farm and rural conditions. *Trop. Anim. Prod.* 8 (2): 90.
- Rahman, T. and Iyer, P. K. R. (1980). *Studies on pathology of ovine pneumonia*. *Vet. Bull.* 50 (5):2923.
- Ramirez, R. and Pijoan, C. (1980). Annual frequency of pneumonic lesions among the goats and lambs slaughtered in Mexico. *Vet. Bull.* 50 (9) :5881.
- Ray, D. K., Negri, S. K. and Srivastava, P. S. (1978). Note on occurrence of metacestodiasis in goats in Tarai of Uttar Pradesh. *Helm. Abstr.* 47(10): 4470.
- Rodriguez, J. L., Poveda, J. B., Oros, J., Herraiez, P., Sierra, M. A. and Fernandez, A. (1995). High mortality in goats associated with the isolation of a strain of *Mycoplasma mycoides sub sp. mycoides* (large colony Type). *Journal of Veterinary Medicine* (42 (10): 587-593.
- Romboli, B., Pellegrin, N. and Braca, G. (1975). *Cysticercus tenuicollis* infection in the lungs of lambs: pathology and histopathology. *Vet. Bull.* 45 (6): 3214.
- Rushton, B., Sharp, J. M., Gillmour, N. J. L. and Thompson, D. A. (1979). Pathology of an experimental infection of specific pathogen-free lambs with parainfluenza virus type 3 and *Pasteurella haemolytic*. *J. Comp. Path.* 89:321-329.
- Sadana, J. R., Purohit, V. D. and Kalra, D. S. (1980). *Incidence and pathology Of verminous pneumonia in sheep and goats*. *Vet. Bull.* 50 (9) 5846.
- Sarker, P. and Battacharyya, H. M. (1975). Caprine pneumonia caused by *Cornenebacterium ovis*. *Vet. Bull.* 45 (11) :6113.
- Scholes, S.F. E. and Kelly, D. F. (1997). Pulmonary venous thrombosis in caprine pasteurella pneumonia. *Journal of Comparative Pathology.* 116(4):415-418.

- Sergany, M. A., Reda, I. M., Sakr, E. E. A. and Abourowash. A. A. (1992). Pathology of PPR in sheep in Egypt. *Jour. Com. Path. Clin.* 5(1): 25-39.
- Shanmugam, S. Shanimugam, A. M. and Jayarajan, S. (1993). A study on the incidence of hydatidosis in sheep and goats in Mettur town. *Cheiron.* 22 (6): 233-235.
- Shariraman, P. K., Rao, R. P. and Naidu, G. N. R. (1982). Goat mortality in Andhra Pradesh. *Indian Veterinary Journal.* 59 (2): 96.
- Sharma, D.N. and Dwivedi, J. N. (1977). Pseudotuberculosis lesions in lung of sheep and goats. *Vet. Bull.* 47(11): 6054.
- Sil, B. K., Rahman, M. M., Debnath, N. C., Tanner, M. J F. A., Rahman, M. F. and Sarker, A. J. (1996,a), Antibiotic combined anti- PPR hyperimmune serum treatment of PPR infected goats. Presented at the 14th Annual Conference of Bangladesh Society of Microbiology.
- Sil, B. K., Rahman, M. M., Taimur, M. J. F. A. and Sarker, A. J. (1995). Observation of outbreaks of PPR in organized goat farms and its control strategy. Presented at the Annual Conference of the Society of Bangladesh Veterinary Education and Research. December 3, BARC, Dhaka.
- Singh, B. P. and Dhar, D.N. (1988). *Echinococcus granulosus* in animals in northern India. *Veterinary Parasitology.* 28 (3): 261-266.
- Singh, S. V., Mann, H. S., Sharma, D. N., Srivastava, A.K. and Prakash, D. (1995). Pulmonary schistosomiasis in sheep and goats: incidence and pathomorphology. *Indian Journal of Veterinary Pathology.* 19 (1): 38- 39.
- Singh, S. V., Sharma, D. N., Srivastava, A. K., Singh, H. (1995). Pulmonary aspergillosis in sheep and goats: incidence and pathomorphology. *Indian Journal of Veterinary Pathology.* 19 (1): 35-37.
- Smith, H. A. , Jones, T. C. and Hunt, R. D. (1972). *Veterinary Pathology.* 4th edition. Lea and Febiger, philadelphia, pp. 765-795.

- Sobein, M. A., Youssef, H. A. and Al- saif, M. (1998). Public health importance of hydatid cysts in slaughtered sheep and goats in El-Gassin, Saudi Arabia, Assiut-Veterinary- Medical-Journal. 39 (78): 194-200.
- Stipkovits, L. and Schimmel, D. (1978). Occurrence of *Mycoplasma ovi pneumoniae* in sheep. Vet. Bull. 48 (1): 89.
- Thorley, D. C., Boyes, B. W. and Davies, D. H. (1978). Sub-clinical pneumonia in lamb. Vet. Bull. 48 (2): 964.
- Tkachuk, S. O., Lusia, P., Welsh, R. D. and Prescott, J. F. (1998). *Rhodococcus equi* infections in goats. Veterinary Record. 143 (11): 311-312.
- Ugochukwu, E. I. (1986). Isolation and identification of aerobic pathogenic bacteria from pneumonic lungs of goats suffering from pneumonia - enteritis complex. Vet. Bull. 56: 4990.
- Umur, S. and Aslantas, O. (1993). Prevalence and economic importance of hydatidosis in ruminants slaughtered in Kars municipality slaughterhouse. Turkiye- parazitoloji- Dergisi. 17 (2):27-34.
- Upadhyaya, T. N. and Rahman, T. (1993). Prevalence and Pathology of caprine pneumonia in Assam. Journal of Assam Veterinary Council. 3: 47-49.
- Utpal, D., Das, A. K. and Das, U. (1998). Cystic hydatidosis of food animals in Greater Calcutta. Indian Veterinary Journal. 75 (4): 387-388,
- Verma, T. K. (1980). Hydatid disease in food animal and man. Helm. Abstr. 49:112.
- Verma, T. K. and Ahluwalia, S. S. (1991). Prevalence of *Echinococcus granulosus* infection in domestic animals in central and Western Uttar Pradesh. Pashudhan- Anushandhan. 1 (2): 1-6.
- Zubaidy, A. A. and, Sokkar, S. M. (1979). Studies on ovine adenomatosis in Iraq. Indian Vet. Jour. 56(5): 360-362.

Zamri, S. M., Effendy, A. W. M., Maswatt, M. A., Sheikh, O. A. R. (1996). The goat as a model for studies of pneumonic pasteurellosis caused by *Pasteurella multocida*. *British Veterinary Journal*. 152 (4): 453-458.

