

**HEPATOPATHOLOGICAL DISORDER OF CATTLE
ENCOUNTERED AT SADAR UPAZILA OF
THAKURGAON DISTRICT**

A Thesis

By

SAGAR BASAK

Registration No. 1305078

Semester: January- June, 2014

Session: 2013-2014

**Master of Science (M.S.)
in
Pathology**



**Department of Pathology and Parasitology
Hajee Mohammad Danesh Science and Technology University
Dinajpur-5200**

June, 2014

**HEPATOPATHOLOGICAL DISORDER OF CATTLE
ENCOUNTERED AT SADAR UPAZILA OF
THAKURGAON DISTRICT**

A Thesis

By

SAGAR BASAK

Registration No. 1305078

Semester: January- June, 2014

Session: 2013-2014

Submitted to the

Department of Pathology and Parasitology

Hajee Mohammad Danesh Science and Technology University, Dinajpur,

In partial fulfillment of the requirements for the degree of

Master of Science (M.S.)

in

Pathology

Department of Pathology and Parasitology

Hajee Mohammad Danesh Science and Technology University

Dinajpur-5200

June, 2014

10178
13.6.16

**HEPATOPATHOLOGICAL DISORDER OF CATTLE
ENCOUNTERED AT SADAR UPAZILA OF
THAKURGAON DISTRICT**

A Thesis

By

SAGAR BASAK

Registration No. 1305078

Semester: January- June, 2014

Session: 2013-2014

Approved as to style and contents by



Dr. Md. Nazrul Islam
Research Supervisor



Dr. Md. Haydar Ali
Research Co-Supervisor



(Dr. Md. Haydar Ali)
Chairman
Examination Committee
&
Chairman

Department of Pathology and Parasitology

Hajee Mohammad Danesh Science and Technology University
Dinajpur-5200

June, 2014

ACKNOWLEDGEMENT

All praises are due to the Almighty God, who kindly enables the author to complete the present research work successfully and to submit the thesis leading to Master of Science (MS) degree in Pathology.

The author expresses his profound indebtedness and sincere gratitude to his honorable teacher and research supervisor, Dr. Md. Nazrul Islam, Associate Professor, Department of Pathology and Parasitology (PPS), Hajee Mohammad Danesh Science and Technology University, Dinajpur (HSTU), for his valuable advice, suggestion's, guidance and keen interest that he took in preparing this thesis. His constructive criticism, painstaking endeavors in going through the manuscripts and his demands for thoroughness in caring out the present work will be remembered with gratitude. I am also grateful to him for his co-operation and skill for the photography and photo-micrography.

The author thanks to his reverend beloved teacher and Research Co-supervisor, Dr. Md. Haydar Ali, Assistant Professor and Chairman, PPS, HSTU, Dinajpur, for his advice and guidance throughout this research work,

The author would like to acknowledge his respected teachers Professor Dr. S. M. Harun-Ur-Rashid, Dr. Md. Mominul Islam, Assistant Professor and Dr. Md. Golam Azam, Lecturer, PPS, HSTU, Dinajpur, for their valuable advices, constant help, continuous encouragement and contribution in completing the thesis.

The author would also like to thanks her co-workers Dr. Pobitra Kumar, Dr. Abdur Rouf, Dr. Shabnam Mostary, Dr. Md. Assaduzzaman Jemy, Dr. Md. Raju Ahmed and Dr. Shakila Reza for their encouraging attitude, kind help and all-out support in the entire period of the research work,

Finally, the author is expressing ever indebtedness to his beloved father, mother, sister, and brothers for their blessings and inspiration through which he got freed from all kinds of tiredness and anxiety through out the research period.

The Author

June, 2014

ABSTRACTS

Hepatopathological disorder of cattle of sadar upazila of Thakurgaon district was investigated and encountered according to etiological agents. The duration of the study was six months ranging from January to June, 2015 and the samples were collected from different slaughter houses of sadar upazila and brought to pathology laboratory under the Department of Pathology and Parasitology, HSTU, Dinajpur for detailed examination. The gross morbid lesions were recorded as per as etiological agent. The samples were preserved at 10% formalin; trimmed, processed, paraffinized, sectioned, stained with Hemotoxyline and Eosin (H & E stain) and examined under microscope using different objections. The lesions were grossly characterized as mild to moderate hepatic damage, cystic formations, abscessation. The incidence of fasciolosis showed the highest position (68.75%) followed by hydatidiosis (23.43%), cirrhosis (12.5%), abscess (6.25%) and mixed infection (7.81%). Among the investigation it was found that the incidence in female is 54.54% for female and 45.45% for male animal in case of fascioliasis, 60% female and 40% male for hydatidosis, 62.5% for female and 37.5% for male in case of cirrhosis, 75% for female and 25% for male in case of abscess, , 40% for female and 60% for male in case of mixed infection.

CONTENTS

CHAPTR	TITLE	PAGE
	ACKNOWLEDGEMENT	iv
	ABSTRACT	v
	CONTENTS	vi
	LIST OF TABLES	viii
	LIST OF FIGURES	ix
	LIST OF GRAPHS	x
	ABBREVIATIONS AND SYMBOLS	xi
1	INTRODUCTION	1-3
2	REVIEW OF LITERATURE	4-21
3	MATERIALS AND METHODS	22-27
	3.1 Experimental animal	22
	3.2 Experimental area	22
	3.3 Research duration	22
	3.4 Pathological examination	22
	3.4.1 Macroscopic examination	22
	3.4.2 Histopathological study	23
	3.4.2.1 Materials required for histopathology	23
	3.4.2.2 Processing of tissue for histopathology	24
	3.4.2.3 Routine Hematoxylin and Eosin staining procedure	25
	3.4.2.4 Staining protocol	26
	3.5 Experimental Lay-out	27
4	RESULTS	28-42
	4.1 Fascioliasis	28
	4.1.1 Gross changes	28
	4.1.2 Histopathologic changes	29

CONTENTS (CONT...)

CHAPTER	TITLE	PAGE
	4.2 Hydatidosis	29
	4.2.1 Gross changes	29
	4.2.2 Histopathologic changes	30
	4.3 Cirrhosis	30
	4.3.1 Gross changes	30
	4.3.2 Histopathologic changes	30
	4.4 Abscess	31
	4.4.1 Gross changes	31
	4.4.2 Histopathologic changes	31
	4.5 Mixed infection	31
	4.5.1 Gross changes	31
	4.5.2 Histopathologic changes	32
5	DISCUSSION	43-46
	5.1 Fascioliasis	43
	5.2 Hydatidosis	45
	5.3 Cirrhosis	45
	5.4 Abscess	46
	5.5 Mixed infection	46
6	SUMMARY AND CONCLUSION	47-48
	REFERENCES	49-58

LIST OF TABLES

TABLE NO.	TITLE	PAGE
1	Number of disease found during the investigation period from January 2014 to June 2014	33
2	Showing distribution of the pathological conditions in relation to sex	34

LIST OF FIGURES

FIGURE NO.	TITLE	PAGE
1	Fascioliasis affected hepatic areas (Fibrotic area)	38
2	Destruction of hepatocytes and extravascular erythrocytes	38
3	Hydatidosis (caseatic sports with dystrophic calcification)	39
4	Distended cords with dilated central vein	39
5	Cirrhosis (Focal necrotic area, whitish spots)	40
6	Proliferated Fiber Connective Tissue with the pre-existing hepatic cells	40
7	Abscess filed up with creamy exudates	41
8	Hepatocytic destruction with obliteration of hepatic cords as well as architecture structures of hepatic lobules	41
9	Mixed infection (Mass fibrotic area)	42

LIST OF GRAPHS

FIGURE NO.	TITLE	PAGE
1	Graphically representation of different disease condition	35
2	Graphically representation the ratio of male in different disease condition.	36
3	Graphically representation the ratio of female in different disease condition.	37

ABBREVIATION AND SYMBOLS

$^{\circ}\text{C}$: Degree celcius
%	: Percentage
<i>et al</i>	: And his associates
etc.	: Etectera
Fig	: Figure
g	: Gram
cm.	: Centemetre
hr	: Hour
H & E	: Hematoxylin and Eosin
HSTU	: Hajee Mohammad Danesh Science and Technology University
lbs	: Pounds
min	: Minute
ml	: Milliliter
mm	: Millimeter
MS	: Master of Science
No.	: Number
Sec	: Second
UK	: United Kingdom
USA	: United States of America
WHO	: World Health Organization



CHAPTER I
INTRODUCTION

CHAPTER I

INTRODUCTION

Cattle is an domesticated animal in Bangladesh, which plays an significant role to improve agricultural production by throwing of large quantities of dung, by yielding milk and meat of high caloric standard to meet up our protein requirements, by earning great amount of foreign exchange from exported skin and bones (byproducts) and protect our lands from Contamination of artificial fertilizer by yielding natural manure. The total population of cattle in our country is about 24.17 million in the year 2009 (Department of Livestock Services, 2009).

Liver is the largest solid gland of the body, which reddish in colour in fresh condition. In adult cow the weight of liver is about 3-5 kg . It is located in the right side of the abdominal cavity in an oblique downward and forward direction, which extends from lumbocostal angle to the level of 7th to 8th rib and is kept attached in the abdomen with five ligaments. It have also two surfaces and four borders. The liver acts as a storage organ for glycogen, fat and some vitamins. It is also responsible for the synthesis of plasma proteins including fibrinogen, prothombin and heparin, bile formed in the liver, is required for the absorption of fats, calcium and fat soluble vitamins from the intestine. It also acts as a important organ of metabolism for fats, carbohydrates and proteins and also act as an important centre for detoxification (Ghosh, 2006).

Liver is one of the significant and essential organs of the body of animals. Liver of cattle is also capable to different kind of disease or conditions, like other animals,, which can lead to malfunction or nonfunction of it and is commonly manifested by sings of jaundice. Bile secretion or detoxification, deposition of carbohydrate, fats, vitamins, some minerals, production of plasma proteins, erythropoiesis in some situations etc, are partly or wholly impaired by affections of liver caused by some etiologic agents such as Fascioliasis, hydatidosis, cirrhosis, hepatic ulcers, abscessation, calcification etc. are the common

conditions of the liver in which the livers are condemned for human consumption. Not only that, these above conditions may also lead to a fatal situation of the animal and if it so happens, the entire financial loss of the owner of cattle has occurred.

Fascioliasis is a major disease, among many parasitic problems of farm animals. This disease also direct and indirect economic impact on livestock production, particularly of sheep and cattle (Hammond 1990; Saleha (1991); Menkir *et al.*, 2007). Swai and Ulicky (2009) state that the total economic loss incurred as a result of condemnation of infected livers due to all causes and fascioliasis was approximately 2,096 US\$ and 1,780 US\$ respectively. Losses due to weight loss were estimated to be 5,943 US\$.

Jampolsy (1979), reported that the economic loss caused by hydatidosis in a slaughter house in 10 Years time in the USSR (previous) amounted to 273000 rubbles. Anwar-UI-Haq (1994) reported an Annual national loss of 26.5 million rupees was estimated due to condemnation of hydatid infected organs during the year 1990. Almost half of the total economic loss was being born by Sindh followed by Punjab 13.3 and 7.3 million rupees. Chemical composition studies of hydatid cystic fluid revealed that the proteins, lipids and glucose were found significantly different in each case of fertile and infertile (Sterile) hydatid cystic fluid.

The liver is one of the vital organs of the body, any damage to the liver parenchyma may lead to impairment of its normal functions which consequently followed by illness of the animals or susceptibility infections which may, even cause death of the animals. Such a considerable economic loss from the condemned livers can hardly be sustained by a poor nation like ours. These losses can be minimized by prevention and control of such diseases affecting the livers after proper investigation. But, there is no systemic investigation on the pathogenesis of cattle liver and pathogenesis of conditions that affects liver has been carried out in our country.

So my research work on the pathological study of bovine liver was, undertaken with the following objects.

- (a) Investigating of necropsy features of bovine liver at Thakurgaon sadar.
- (b) Histomorphometric observation of the affected livers.



CHAPTER II

**REVIEW OF
LITERATURE**

CHAPTER II

REVIEW OF LITERATURE

A careful selection have occurred from different types of enormous publication , according to their importance following veterinary medical themes generally created and distilled to provide the better origin of recent practical fact concerning pathological condition of the cattle liver. In the topic of liver diseases exploration of information obtained from a cautious history, physical test and apporiatly elected clinical and histopathological examination will provide a firm basis for right concept of the related diseases. In the last different decades, there a lot of literature are obtainable on different perspective of functional disorder of the significant organ and the information of literature turn to difficult to explore. In this part of study among different information recent view supposed as a brief and critical guide.

Ross (1966) examined 900 cattle of which 80% were found to be infected. Immature flukes were found from June to April with peak levels between Octobers to December but the highest adult burdens were observed between Januarys to March. He found the developing liver flukes produced constant microscopic lesions in the liver of Cattle between 3rd and 6th week post infection. Red superficial tract was produced and from the 7th to 9th week localized red hemorrhagic plaque lesions developed prior to entry to the flukes to the bile ducts. On entry to the bile ducts, fibrosis of the duct wall and acinar hyperplasia results with recognizable calcification in the wall. He added that the inhibited flukes were found to survive in the plaque lesions in the parenchyma for as long as one year.

Detail gross and microscopic hepatic changes were studied by **Dow et al., (1967)** with experimental *Fasciola hepatica* infection in calf liver which was disclosed by the presence of migratory flukes into the bile ducts, resulted in proliferation of the epithelium producing a glandular mucosa. Destruction of the lining which become fibrosed and then calcified due to the activity of the fluke was also

recorded. According to the authors fibrosis in the liver in chronic fascioliasis may result from (i) the parenchymal damage caused by migratory flukes and cause damage in the portal tracts, following the entry of the fluke into the bile ducts.

Dow et al., (1968) described the histopathological appearance in experimental infection with *Fasciola hepatica* in lamb. Two phases of parenchymal migration of the parasite such as free migrating and localized phase of migration before entry into the bile ducts were observed. Hepatic cells regeneration were indicated but hepatic fibrosis were minimally reported. The localized phase of migration was associated with a unique peripheral palisade of giant cells in the flukes in the bile ducts produce fibrosis of duct walls. However, remained pliable and expanded to accommodate the parasite and calcification was never observed.

Sheikh and Hussain (1968) examined 210 animals at abattoir in Lahore, West Pakistan, During February to august 1967 revealed *Echinococcus granulosus* cysts in 52 of 148 buffaloes (35%) and 17 of 62 cattle (27%). Using various cysts fractions as antigen, casoni's skin test failed to give any specific reaction in the cattle and buffaloes.

The gross and histopathology o the bovine liver due to fascioliasis was studied by **Irfan and Lee (1968)**. They found areas of hemorrhagic tracts caused by the migrating flukes which were infiltrated by eosinophils. Some of the bile ducts show hyperplasia and increased secretory activity. In many areas cirrhosis accompanied by pressure atrophy, fatty change and necrosis of the parenchymatous cells were reported. Deposition of hemosiderin and in some cases nodules of mononuclear cells was also observed.

Sengupta and Iyer (1968) studied the changes in advanced stages of *Fasciola gigantica* infection in the buffalo livers which were characterized by thickening of the portal triads with fibrous tissues extending into the neighboring liver parenchyma, and resulting in monolobular or perilobular cirrhosis. The hepatic arterioles exhibited median hypertrophy with sub-endothelial proliferation of

connective tissue. The bile ducts revealed hyperplastic changes of the lining epithelial cells, which at times assumed papillomatous proportion. Most of the ducts were, however devoid of the lining epithelial cells as a result of the movement of flukes with in the ducts. Numerous eggs were seen in the bile ducts and in the parenchyma the granulomatous lesions due to eggs were reported.

Cameron and Webster (1969) described the histogenesis of the hydatid cyst on the livers of bovines, pigs, sheep, deer and equines which followed a generally similar pattern in all species. According to them, the hydatid cyst composed of 3 layers. (i) The living cyst or nucleated layer was a thin walled single layered cell membrane enclosing a slightly clear sterile fluid and budding inwards as brood capsules. (ii) The laminated layer was a tough elastic layer and consisted of chitin or keratin related material and calcium. It increased with age and prevented the structure of bacteria. (iii) The adventitia- the growing cyst caused a pressure atrophy of the adjacent liver tissue and irritation of the metabolites caused the formation of toxic epitheloid giant cell zone in which there was a heavy reduction of eosinophils. The cells radiated from the cyst and had some degree of cloudy swelling of actual necrosis. The zone gradually subsided and formed fibroblast cells.

According to **Rahko (1969)** the changes of natural *Fasciola hepatica* infection in cattle included frequent thrombosis and haemorrhages, extensive disintegration and coagulative necrosis of hepatic cells and abundant infiltration of inflammatory cells.

According to **Bhuyan (1970)** the percentages of paralyzed livers of cattle, Buffalos, goats and sheep were 71.55, 100, 30 and 14.6 respectively. He estimated that a total loss of protein from condemned livers in the then East Pakistan (Now Bangladesh) during the year 1969 was 38, 90, 826 Ibs and its economic loss was Rs.50, 34,625.00.

Pullan et al., (1970) studied the pathogenesis of *Fasciola hepatica* infection in sheep. The infection was occurring due to presence of 5500 to 12000 metacercariae. In the more acute syndrome, death occurs 7 to 9 weeks after infection, with more than 1400 immature flukes in the liver parenchyma but more in the bile ducts. In less acute form, death occurred 9 to 15 weeks after infection with between 500 to 2300 flukes in liver, mostly of the bile ducts. In those hosts which survived for more than 12 weeks, the flukes were immature, the gall bladder was very dark usually contained blood clots and the liver was more fibrotic.

Maliki and Mohiyuddin (1970) described the obliterating endophlebitis of hepatic veins affecting the portal circulation is an infrequent condition most commonly caused by thrombosis. Chronic occlusion, relatively more common, is a complication of intrahepatic disease compatible with survival for months. Literature in animal pathology revealed very reports and the disease is found affecting uterine veins, the supramammary veins in suppurative bronchopneumonia or tuberculosis as reported by **Runnels et al., (1965)**. Hence a case of obliterating endophlebitis in a buffalo involving portal circulatory system has been reported.

Grossly- Liver had multiple nodulation, hard and shrunken, stimulating hab nailed appearance. It was congested and hemorrhagic in the unaffected areas. Once incision, the liver was quite tough and rubber like.

Enormous amounts of connective tissue were observed in the wall of the exposed portal vessels narrowing the lumen which contained yellowish red dirty fluid. No calcification or grittiness of the organ was observed. Histologically- the section revealed hyperplastic, proliferative and infiltrative changes. The infiltration preliminary consisted of mononuclear leucocytes, lymphocytes and giant cells, diffusely scattered in the abundant process was most intense in the media and adventitia and varied in character with the stages of its development.

Several of the portal veins have been converted into fibrous cords which appeared spongy vascular structure due to canalization. The proliferation was chiefly due to the leucocytes in early stages of the development had round or oval and faintly stained nuclei with less chromatin granules or materials, while the matured cells were smaller in size with deeply stained nuclei due to compact chromatic material. The normal architecture of the hepatic parenchyma was disturbed and distorted with lobulation atrophy and other degenerative changes. All the major vessels such as the portal veins and even the arteries were thickened.

Malik and Prakash (1972) studied the structure of liver parenchyma, and according to them it was similar in the two species. Buffalo liver had a thinner capsule than that of cattle. The area of the hepatic lobule and central vein and the size of hepatic cells were slightly larger in buffaloes than in cattle but this differences were statistically significant.

According to **Smith *et al.*, (1972)** the immature flukes spent about six weeks in the liver parenchyma, causing damage to liver and the larvae lie in a pool of blood fibrin and cellular debris. In that case, neutrophil, eosinophils and lymphocytes became the part of the infiltrate and in older lesions, macrophages and epitheloid cells became increasingly numerous. Later the biliary epithelium became proliferated partial or complete occlusion of bile ducts and wall of the bile ducts become fibrosis in the perilobular connective tissue.

According to them livers containing several or many minute yellowish foci of necrosis, 1 or 2 mm. in diameter scattered without grossly apparent relation to the lobular architecture and occurring most often in well fattened young cattle, were the so dust livers. They consisted of collections of hepatic epithelial cells in a state of coagulative necrosis or in the process of disappearing, mingled with or surrounded by a thin sprinkling of neutrophils and lymphocytes. All saw dust livers did not become abscesses.

They reported the hydatid cysts had the tendency to produce endogenous daughter cysts which displaced the vital tissues. The growth of cysts was slow and was encapsulated by dense fibrous tissue of the host. The larva had an outer dense laminated wall without nuclei which enclosed a germinal layer and from the brood capsules arose.

They also stated that "Sawdust livers" and Telangiectasis were often concurrent and probably predisposed to the hepatic abscesses. They cited that the incidence of abscesses approximated 5 percent of the cattle slaughtered throughout the United States, reached 10 percent in the Rocky Mountain area and 100 percent in some shipment from certain-feedlots. The numbers of abscesses in a liver typically were between 3 to 8 and their size was from 2 or 5 cm. in diameter. They stated that the early lesion was one of coagulative necrosis and the true abscesses consisting of encapsulated pus represented older processes. They concluded that the abscesses were at first necrotic areas and later, chronic abscesses with the granulomatous reticulo-endothelial type of reaction.

Haroun and Hussein (1975) were made an investigation of the pathological, haematological and biochemical aspects of naturally occurring bovine fascioliasis in the Sudan. 228 animals infected with *Fasciola gigantica* and 25 non-infected controls were used in the study. The infected cattle revealed emaciation, typical liver pathology, and, occasionally, lesions in the lung and the pancreas.

Runnels et al., (1976) recorded that the young hepatic abscesses were sharply defined, light yellow, greenish yellow or dirty gray foci with pulpy or creamy centers. They were odorless or foul smelling. The old abscesses varied in size, were encapsulated and calcified.

Elmossalami and Darweish (1977) reported that *Fasciola hepatica* predisposed to bacterial infection. In the abattoir in Cairo, Egypt, they examined 15 normal sheep livers and 66.7 percent were found infected with various bacteria. 30 livers containing *Fasciola hepatica* were examined and all were infected with bacteria.

Uzoukwu and Ikeme (1978) reported hepatic changes in natural *Fasciola gigantica* infections of the Fulani zebu cattle. Histopathologically, they observed 3 types of chronic reaction: numerous small abscesses containing *Fasciola* larvae or eggs with cellular reactions and calcifications; marked inter lobular fibrosis, proliferation of bile ducts and peribiliary fibrosis in absence of parasites; and nodular growths consisting of hyperplastic bile ductules lacking secretory ability.

According to **Magzoub and Kasim (1978)** the prevalence of fascioliasis was highest when rainfall was higher and irrigation scheme were more developed.

Salo et al., (1978) reported that the main source of fascioliasis in dairy cattle was rice straw and they found hepatic abscesses in all cases in acute fascioliasis in dairy cattle.

Verma (1978) reported that 6.88% of the animals slaughtered in bareilly, India, harbored hydatid cysts. 130 of 928 buffaloes, 18 of 346 sheep, 11 of 362 goats were found to be harbor fertile hydatid cyst and most of the cysts were recovered from the lungs.

According to **Jampolsy (1979)** the economic losses caused by hydatidosis in a slaughter house in 10 years time in the USSR (previous) amounted was 273000 roubles.

Folaranmi et al., (1979) examined one thousand and twenty-four cattle, 550 sheep and 1,748 goats slaughtered in a rural slaughter slab during 1973 to 1975 were examined for evidence of liver fluke infections. The prevalence rate of *Fasciola gigantica* and *Dicrocoelium hospes* infections was respectively 65.4% and 56.0% in cattle, 40.8 and 13.1% in sheep and 17.6 and 5.2% in goats. Other trematodes detected were *Schistosoma bovis* and paramphistomes. The seasonal incidence of *F. gigantica* as well as of *D. hospes* was highest during and directly after the rainy season. The lower prevalence rate of *F. gigantica*, especially in the younger animals.

Al-Abbassy et al., (1980) examined slaughtered sheep, goat, cattle and camels at Baghdad abattoir, Iraq for hydatid cysts and recorded 20% of camels, 5.9% of sheep and 4.9% of cattle were positive. They reported that, of 450 goats, 23 (5.1%) were infected among which (2%) had the fertile cysts and the cysts were mainly found in the liver.

Wensvoort et al., (1980) stated that in chronic bovine fascioliasis marked perilobular fibrosis was present 8 weeks after infections, increased severity upto 12 weeks and after 20 weeks it decreases simultaneously, an infiltration with eosinophils and edema appeared in the portal tracts. There was proliferation of biliary epithelium followed by distinct cholangioles.

Prasad and Mondol (1980) studied on hydatidosis at Patna and Ranchi in India. Of 1480 goats killed 102 (6.98) had hydatid cysts. Males were more frequently infected (6.33) than females (0.95). Among them 18.8% cysts occurred in liver and 71.9% of the cysts were fertile.

According to **Gupta (1981)** the liver was grossly enlarged, yellowish and had rounded edges. Microscopically the liver showed portal hepatitis, fatty changes and large eosinophilic intracytoplasmic inclusion bodies in the hepatocytes. The inclusion bodies were surrounded by halo and were stained bright red with Shorr's triple stain.

Shaba et al., (1983) examined livers of 4020 domestic animals from south west Iran indicated that 20.5% of the animals are infected with *F. gigantica* and/ or *F. hepatica*. The infection rates 91.5% for buffaloes, 49.2% for cows, 295 for sheep and 11.25 for goats.

Shaikh et al., (1983) from February 1978 to February 1981 in Bangladesh, examined 526 cattle, 315 buffaloes, 178 sheep and 245 goats at slaughter houses of Dhaka, Narayanganj, Munshiganj, Joydevpur, and Savar, *Fasciola gigantica* was found in 59.3%, 78.7%, 27% and 18% respectively. *Echinococcus* (hydatid cysts) in 14.8%, 41.6%, 14.0% and 0.8% and *Coenurus cerebralis* in 0.6% of

buffaloes and 4.1% of goats numbers during June-September, leading to high incidence of infection during October to November.

Yaman et al., (1985) state that the prevalence of hydatid disease was investigated in 704 sheep, 391 goats and 280 cattle slaughtered at two abattoirs in North Jordan. The infection rates for these animals were 4.0, 3.6, 11.4 and 8.8%, respectively. In general, older animals had higher infection rates than younger ones. The percentage of infected animals that had fertile cysts was 66.7% in camels, 34.3% in cattle, 28.6% in goats and 7.1% in sheep. Out of 143 single cysts recovered from cattle, 52.4% were fertile; 29.2% of cysts in goats and 8.0% of those in sheep were fertile. However, infected sheep had more fertile multiple cysts than other animals.

A survey of 361 cattle and 254 buffaloes was made by **Upadhyay and Sahai (1986)** at Ranchi, India which revealed 53.5% (136) of the buffaloes to be infected by *Gigancotyle explanatum* mostly in the liver and bile ducts. No cattle were infected. A that this was directly related to the life cycle and availability of the intermediate host snail, *Gyraulus convexiusculus*. Sails are available in large numbers during June-September, leading to high incidence of infection during October to November.

Histochemical studies by **Upadhyay et al., (1987)** revealed marked depletion in polysaccharide complex substance, glycogen and acid mucosubstance in the hepatic cells of the liver of buffaloes (*Bubalus bulabis*) infected with *Gigantocotyle explanatum*, where as these substance showed strong possibility in different portions of flukes and also in epithelial cells of the bile ducts. On the other hand, histopathological alterations were mainly confined to the bile ducts. In cut sections, the parasites were seen in the lumen of the ducts and the epithelial cells were showing hyperplasia and hypertrophy. There was also peribiliary cirrhosis, particularly around the affected bile ducts. Parasites were lying free in the lumen of the bile ducts or were firmly attached to the mucosa. Infected livers were enlarged, pale and hard studies with hemorrhagic spots, the bile ducts were congested with papillary projections of the mucosa. Moderate mononuclear cells

infiltration of the lamina propria and hyperplasia and hypertrophy were evident in the bile ducts and there was severe peribiliary cirrhosis. The portal tract also showed monocytic infiltration.

Swarup et al., (1987) studies on the revalence and clinicopathology of naturally infected *Fasciola gigantica* and *Gigantocotyl explanatum* in buffaloes which showed 61.78% infection with either of the two or both type of parasites. Highest infection rate was observed for *Fasciola gigantica* (29.26%) and lowest for *Gigantocotyl explanatum* (19.51). The histopathological changes in liver associated with 2 types of infections have been described. *Fasciola gigantica* infection was more harmful than *Gigantocotyl explanatum* infection in livers of buffaloes.

Histopathological study of **Swarup and Pachauri (1987)** showed that the *Fasciola gigantica* infected organs showed typical lesions of early chronic stage of infection, most important being disruption of hepatic cells loss of normal architecture of liver parenchyma, cellular infiltration and fibrotic and hyperplastic changes in the bile ducts. The infected livers had significantly low fat and high protein content without any significant changes in ash and energy contents. Pas positive substances were extensively depleted in infected liver parenchyma, evenly distributed in non infected hepatic cells and abundant in parasitic organs. The alkaline phoshatase activity in the infected livers was comparatively low. No changes in lipid distribution could be demonstrated in the liver section from infected and control buffaloes.

Hammond (1990) worked on different helminthes disease and stated that among many parasitic problems of farm animals, fascioliasis is a major disease, which imposes direct and indirect economic impact on livestock production which causes most economic losses of the livestock industry.

Saleha (1991) stated that the common causative agents are *Fasciola hepatica* and *F. gigantica* which require various species of *Lymnaea*, fresh water snails, as their intermediate hosts. The epidemiology of the disease and its prevalence in

Malaysia is mentioned briefly. The disease causes considerable impact on the economy of the livestock industry.

Dhote *et al.*, (1992) studied the hepatic lesions in cattle. Various pathological lesions encountered (67/133, 50.4%) were hydatidosis (23.3%) abscess (6%) schistosomiasis (0.8%) hemorrhage (8.3%) Granular degenerative changes (3.8%) cirrhosis (5.3%) fatty changes (1.5%) and necrosis (1.5%). In similar studies the occurrence of pathological conditions was found to be 22.4% and 29.0% by earlier workers. Among the various lesions observed hydatidosis was most common (23.30%) even then its occurrence was lower than those reported earlier.

Bettini and Marcato (1992) study of 66 primary hepatic tumours was carried out on cattle. These consisted almost entirely of adult females. Fifty hepatocellular tumours (10 adenomas and 40 carcinomas) 10 cholangiocellular tumours (three adenomas and seven carcinomas) two cavernous haemangiomas, two haemangioendothelial sarcomas, one fibroma and one Schwannoma were diagnosed. The 50 hepatocellular tumours were classified into adenomas (20 per cent) and carcinomas (80 per cent) both prevalent in the solitary macro nodular form. The hepatocellular carcinomas were divided into six groups based on their distinctive histological arrangement and the morphology of the neoplastic cells: trabecular (55 per cent) pseudo glandular (10 per cent) solid (12 per cent) scirrhous (12 per cent) pleomorphic (7 per cent) and fibro lamellar (2 per cent). Twenty-seven of 50 hepatocellular tumours (54 per cent) were associated with features of blood-filled lakes resembling telangiectasis within the neoplastic tissue.

Anwar-Ul-Haq (1994) the study under report revealed investigations on economic losses, biometry and chemical composition of hydatid cyst in cattle. Five thousand cattle of either sex were examined at slaughter in Faisalabad abattoir during 1988 to 1990. A prevalence of hydatidosis in 35 percent cattle was recorded. The hydatid cyst was found in various organs i.e. liver, lungs, spleen,

heart and kidneys. Liver contained 25.31 percent cystic burden while lungs and spleen were having 47.31 and 1.83 percent of cysts, respectively.

Johnson et al., (1999) examination of 675 caprine livers from a slaughterhouse in the Greater Muscat area in the Sultanate of Oman revealed that 63 (9.3%) exhibited gross pathological changes leading to condemnation of this organ. Forty of these livers (71.4%) exhibited one major abnormality, whereas the remaining 28.6% had two or more lesions. The most frequently occurring disorder was diffuse hepatic lipidosis (4.0%) followed by bacterial associated abscesses (2.4%) cysticercosis (1.9%) and eosinophilic granulomata (1%). Although the cause for the hepatic lipidosis was not determined it appeared to be a reversible condition based on the absence of degenerative nuclei within the affected hepatocytes. Conditions observed in only a single liver were subcapsular (non-parasitic) cysts, focal necrosis, micronodular cirrhosis, extensive bile duct proliferation and diffuse haemorrhage.

Anwar et al., (2000) was studied the prevalence and biometry of hydatidosis in 5000 cattle of either sex. Magnitude of prevalence was 35.0 %. The hydatid cysts were found in liver (25.31 %) lungs (47.31 %) and spleen (1.83 %). Mixed infection of hydatid cysts was found both in male (23.72 %) and female (26.18 %) cattle in liver, lungs and spleen. Lungs were the most commonly infected organ both in males (29.32%) and females (49.55%). Irrespective of sex, lungs had the highest fertility rate (76.93%) with the highest number and largest size of cysts.

Bostelmann et al., (2000) described the hepatic lesions caused by *Fasciola hepatica* was conducted in 3 domestic ruminants: cattle, buffaloes and sheep. Liver samples were processed by routine histological methods. The staining procedures included haematoxylin-eosine, Schorr (triple staining) Mallory (triple staining) and toluidine blue. The most frequent lesions found were the following: parasite sections inside the biliary ducts, portal system fibrosis and biliary duct hyperplasia. Lymphocytes, plasmocytes, eosinophils and neutrophils were found in cattle and buffaloes, characteristic of a chronic

disease. The presence of eosinophils in sheep was characteristic of the initial phase of chronic fascioliasis.

Kim-YeonSoo *et al.*, (2001) survey of fascioliasis of Korean native cattle raised in specialized commercial breeding farms and local farms in the Kangwon province of Korea was conducted from November to December 1996 using both intradermal tests and fecal sedimentation techniques. Fecal samples were collected from cattle found to be fascioliasis-positive based on the intradermal test. Liver tissues were randomly collected from an abattoir for histopathological examination of liver fluke infection. Among the 60 faecal samples from positive cattle, eggs of *Fasciola hepatica* were found in 51 (85.0%) on the basis of the sedimentation technique. According to the cattle raising areas, 26.7 (20/75 head) and 29.4% (40/136 head) of cattle in Wonju and Wheongsung, respectively, tested positive in the intradermal test. On the basis of age, 7 out of 100, 41 of 93, and 12 of 18 head in the 1-3, 4-6 and 7-10 years age groups, respectively, gave positive results in the intradermal test. Overall infection rates with fluke larvae in the slaughtered cattle at an abattoir in Wonju was 24.7% (37/150 head). Based on histopathology, liver lesions such as inflammation; infiltration with eosinophils, polymorphonuclear cells, mononuclear cells and multinucleated giant cells; proliferation of connective tissues; calcification and abscess formation, were observed.

Atasever and Vural (2002) worked on 3470 livers of beef cattle slaughtered by the Ankara Meat and Fish Company was inspected. In these animals, 82 livers had telangiectasis, and the incidence of lesions was 2.3%. They were characterized grossly by single or multiple red-brown foci, generally 1 to 5 mm in diameter, and occasionally larger. They were located on the parietal surface of the lobus dexter or rarely scattered throughout the organ. Microscopically, dilated sinusoids filled with erythrocytes were observed in initial lesions; the distortion, atrophy and necrosis of hepatocytic cordons were seen in advanced cases. There was no correlation between liver abscesses and telangiectasis.

Sevinc and Basoglu (2002) measure the lipid content in liver biopsies for the determination of the presence and degree of the fatty liver in dairy cows with periparturient diseases. 118 cows were included in the study, of which 25, 23, 25, 23, 10, and 12 had parturient paresis, spontaneous ketosis, abomasum displacement, retained placenta, mastitis, and metritis, respectively. Liver biopsies were performed in the right 11th to 12th intercostal space. Histopathological examinations showed that cows with milk fever, ketosis, abomasal displacement, retained placenta, mastitis, and endometritis also suffer from fatty infiltration of varying degrees, indicating that these diseases are associated with fatty liver. The incidence of fatty liver was 76% in cows with milk fever. Moderate to severe fat infiltration was observed in all ketotic cows except one. Varying degrees of fatty infiltration was found in 21 cows with displaced abomasum. The incidence of fatty liver in the studied cases was 91.5%.

Nagarajan et al., (2007) determine the incidence, severity and clinical significance of fatty liver syndrome in cattle. Fifty cattle and buffaloes brought for treatment at the large animal medical unit of Madras Veterinary College Hospital with a history of recent calving, inappetence and reduction in milk yield were included in the study. The animals showed decreased milk production (30 animals) primary ketosis (8 animals) chronic indigestion (6 animals) and blood parasitism (6 animals). Liver biopsy was performed in all animals. Of the 50 cases examined, histopathological changes such as fatty liver, diffuse hydropic degeneration, focal hydropic degeneration and focal necrosis were observed in 16, 42, 36 and 6% of the animals. Fatty liver was classified depending on the histopathological findings in the biopsy material into mild (0-20%) moderate (20-40%) and severe (more than 40%).

Ahmedullah, et al., (2007) worked on Livers (n = 80) of slaughtered adult buffaloes were examined for pathological changes during the period from July 2006 to March 2007 in two slaughter houses of Barisal district. Livers exhibiting gross alterations were cleaned with normal neutral saline and the changes were recorded. The lesions containing tissue samples were collected in 10% buffered

formalin for fixation. Grossly, *Gigantocotyle explanatum* infection (amphistomiasis) was found in 31.25% and *Fasciola gigantica* infection was in 22.5% cases. Hydatidosis (2.5%) abscesses (3.75%) and haemorrhages (2.5%) were found in the liver. Histopathologically, cirrhosis was found in 31.25% cases. Nodular hepatitis 7.5%, granulomatous hepatitis 5% and parasitic cholecystitis 15% were also recorded during the investigation. Survey showed that the severity of infection with *G. explanatum* 31.25% and *F. gigantica* 22.5% and cirrhosis 31.25% were of highest percentage.

Nagaraja and Lechtenberg (2007) described that liver abscesses in feedlot cattle result from aggressive grain-feeding programmes and are influenced by a number of dietary and management factors. They have a major economic impact on the feedlot industry because of liver condemnation and reduced animal performance and carcass yield. Ruminal lesions resulting from acidosis usually are accepted as the predisposing factors. Generally, control of liver abscesses in feedlot cattle has depended on the use of tylosin, which reduces abscess incidence by 40-70%.

Khan et al., (2008) study reports the prevalence, effects of treatment and cost benefit analysis of bovine fasciolosis in five districts of Punjab Province viz Sargodha, Jhang, Muzaffargarh, Lodhran and Layyah. From each of the five districts, 80 animals were selected and fortnightly screened through standard coprological procedures for a period of one year for the presence of eggs of *Fasciola* species. Of 4800 faecal samples analyzed, 1222 (25.46%) were found positive for fasciolosis. The occurrence of *Fasciola (F.) gigantica* (22.40%) was higher ($P < 0.05$) than *F. hepatica* (3.06%). Highest month-wise prevalence ($P < 0.05$) of fasciolosis was found in winter (39.08%) followed in decreasing order by spring (29.50%) autumn (20.33%) and summer (12.92%). District-wise prevalence of fasciolosis was highest ($P < 0.05$) in Sargodha (40.31%) and lowest in Layyah (11.77%) while other districts were having intermediate values of prevalence of fasciolosis. Species-wise prevalence of fasciolosis was found higher ($P < 0.05$) in buffaloes (30.50%) as compared to cattle (20.42%).

Kakar and Kakarsulemankhel (2008) Investigated that the Prevalence of endo and ecto-parasites in cows and buffaloes were in Quetta city of Pakistan. A total of 396 livers and gall bladders of cows and 340 of buffaloes were selected randomly. Overall prevalence of liver parasites in cows and buffaloes was 45.70 and 37.05%, respectively. The species found in livers of cows were: *Fasciola hepatica* (16.16%) *Fasciola gigantica* (12.37%) *Paramphistomum explanatum* (7.82%) and mixed infections (9.34%). The corresponding values for buffaloes were 11.47, 13.52, 5.58 and 6.47%.

Mwabonimana et al., (2008) was to establish the prevalence and economic significance of fasciolosis in cattle slaughtered at Arusha abattoir in Tanzania. A 3-year database (2005-2008) from the abattoir was retrieved and analysed. In addition, meat inspection was carried out for one month (July 2008) with focus on *Fasciola* infection and its associated economic loss due to liver condemnation. Results from the retrospective study revealed that 8302 (6.7%) livers out of 123790 examined livers were condemned due to fasciolosis. Analysis of primary data (meat inspection) showed that 150 of 469 cattle livers condemned were due to fasciolosis, a relative condemnation rate of 32.0% per month. Based on the current local price of liver, the economic loss per month due to liver condemnation was estimated at Tanzania shillings (TZS) 1,800,000/- (approximately US \$1,500) which summed to TZS 21,600,000/- (US \$18,000) per annum.

Regassa et al., (2009) assessed the status of cystic hydatidosis in cattle slaughtered at Hawassa Municipal abattoir. Out of the total 632 cattle examined visually and manually (palpation and incision) 333 (52.69%) were found harboring hydatid cysts. A significantly higher infection was detected in older cattle ($P < 0.05$, $\chi^2 = 4.36$) than young. Of the total 333 infected, 123 (36.9%) had hydatid cysts only in the lung, 23 (6.9%) in the liver, 12 (3.6%) in the spleen, five (1.5%) in the heart, and three (0.9%) in the kidney while the rest 167 (50.2%) had multiple organ infections. Of the 530 viscera harboring hydatid cysts, the highest (52.83%) was lung followed by liver (34.15%) spleen (9.06%) heart (3.39%) and

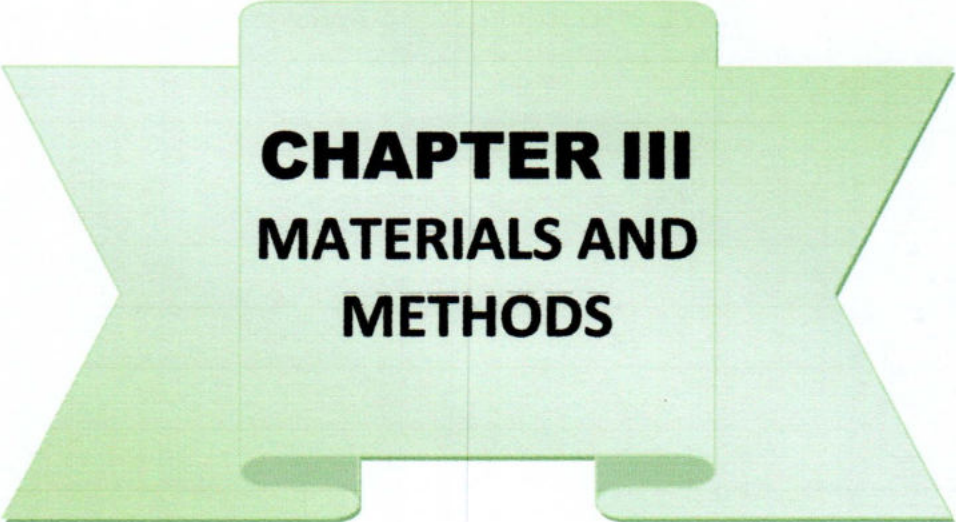
kidney (0.56%). Size assessment made on 874 cysts indicated that 308 (35.3%) were small, 251 (28.7%) medium, 89 (10.2%) large, and 226 (25.9%) were calcified. The distribution of characterized cysts in different organs based on their size was found to be statistically significant ($P < 0.05$).

Swai and Ulicky (2009) carried out a survey in Hai town abattoir during the period of August 2004 to August 2005 (13 months) in order to estimate prevalence and economic importance of bovine fascioliasis in slaughtered cattle. Prevalence of fascioliasis was calculated as the number found infected with *Fasciola*, expressed as the percentage of the total number of cattle slaughtered. A total of 2114 cattle originating from Weruweru-secondary market and local livestock traders were examined. Three hundred and forty one livers (16.1%) of these cattle were condemned for various reasons. Two hundred ninety seven (14.05%) were infected with *Fasciola*. The monthly incidence was highest during the period immediately before and after onset of the short rain.

Ahmed A. M. Ismail, Dessouki A. A. (2012) in 12 month examined 9880 male cattle in the city of ismalia abattoir. Liver abscess found in 181 (12.4%) which followed by liver cirrhosis 79 (5.45%) are found. which cause great economic loss of city of ismalia. Autumn & Summer season is the highest season for infection. The direct economic loss occurred from organ condemnation as the result of pathological lesions as calculated 30 egyptian pound as the average retail price of edible organ per kilogram in ismail city. The estimated annual economic loss from the total organ condemnation was 36480 egyptian pound.

Nabil A. M. Sulmon, Snur M. A. Hossain. Azad K Saedz (2013) examined 50 liver in sulaimini abattoir where 16 sample (32%) showed Neutrophilic infiltration & 10 samples (20%) showed eosinophilic infiltration, 22 sample (44%) showed liver cirrhosis. The presence of mature flukes within the lumen of intra hepatic bile duct which brought a continuous irritating to bile duct. The normal architecture of bile duct are change . It is very harmful to cattle .This condition cause great economic loss.

Kalu E Akpabio & Gloria D. I. (2015) carried out a survey in different in abattoirs in nigeria. The prevalence of between 22.13% to 50.5% of fasciolosis have been found. As a zoonotic importance, therefore fasciolosis should be taken seriously, prevented & controlled at farm level by creating awareness about the public health importance. Economic losses associated with the infection.



CHAPTER III
MATERIALS AND
METHODS

CHAPTER III

MATERIALS AND METHODS

3.1 Experimental animal

The experimental animals of this study were cattle which were submitted for slaughtering in the slaughter house.

3.2 Experimental area

The investigation was carried out in the Department of Pathology and Parasitology, Faculty of Veterinary and Animal Science, Hajee Mohammad Danesh Science and Technology University (HSTU), Dinajpur. Livers of cattle were collected from different slaughter houses of Thakurgaon sadar for detailed pathological examinations.

3.3 Research duration

A total of 64 cattle liver were examined for gross pathological abnormalities during the period from 1st January to 30 June, 2014 and brought for diagnosis to the laboratory of the Department of Pathology and Parasitology in HSTU.

3.4 Pathological examination

3.4.1 Macroscopic examination

A total of 64 livers along with gall bladders showing grossly visible abnormalities were collected for detailed pathological studies. All the macroscopic changes were noted. Incisions were given to the affected area to study the nature of the macroscopic lesions, whenever needed. Presence of any cyst with its size and location in the liver was also recorded. The blood vessels and biliary ducts were opened with the help of scissors and forceps and the liver flukes were collected. The liver was then cut into small slices and the slices were squeezed and macerated in normal saline. After careful removal of larger debris's the smaller ones was washed several times with normal saline until the

supernatant fluid was clear. The sediment was then examined thoroughly for parasites, sometimes with the aid of a magnifying glass. The collected trematodes were washed in normal saline and distilled water for several times and preserved in glycerin alcohol solution which was composed 95 parts of 70 percent ethyl alcohol and 5 parts of glycerine. The parasites were identified in the Department of Pathology and Parasitology, Faculty of Veterinary and Animal Science, Hajee Mohammad Danesh Science and Technology University (HSTU).

3.4.2 Histopathological study

During necropsy, various organs having gross lesions were collected then preserved at 10% formalin, after that processed, sectioned and stained for histopathological studies following a standard procedure (Luna, 1968).

3.4.2.1 Materials required for histopathology

Equipment and appliances:

- Samples (Liver)
- 10% formalin
- Chloroform
- Paraffin
- Alcohol
- Tape water
- Microtome
- Xylene
- Hematoxylin and Eosin stain
- Distilled water
- Clean slides
- Cover slips
- Mounting media (DPX).
- Microscope

3.4.2.2 Processing of tissue for histopathology

1. Collection of tissue and Processing

During tissue collection the following point were taken into consideration-

The tissues were collected in conditions as fresh as possible. Normal and diseased tissues were collected side by side. The thickness of the tissues were as less as possible (5mm approximately).

The tissues (liver) were collected from the Cattle in the Histopathology Laboratory of Department of Pathology and Parasitology, HSTU, Dinajpur.

2. Fixation: 10% formalin was added in the plastic container. (10 folds of the tissue size and weight) and fixed for 3-5 days.

3. Washing: The tissues were trimmed into a thin section and washed over night in running tap water to remove formalin.

4. Dehydration: The tissues were dehydrated by ascending ethanol series to prevent shrinkage of cells as per following schedule.

- ❖ 50% alcohol - one hour
- ❖ 70% alcohol - one hour
- ❖ 80% alcohol - one hour
- ❖ 95% alcohol - one hour
- ❖ Absolute alcohol - three changes (one hour for each changes.)

5. Cleaning: the tissues were cleaned in chloroform for 3 hours to remove ethanol (1 and half hr in each, two changes).

6. Impregnation: Impregnation was done in melted paraffin (56- 60°C) for 3 hours.

7. Embedding: Paraffin blocks containing tissue pieces were made using templates and molten paraffin

8. Sectioning: Then the tissues were sectioned with a microtome at 5-6 μ m thickness. The sections were allowed to spread on lukewarm water bath (40-45 °C) and taken on a glass slide. A small amount of gelatin was added to the water bath for better adhesion of the section to the slide. The slides containing sections were air dried and stored in cool place until staining.

3.4.2.3 Routine Hematoxylin and Eosin staining procedure

□ Preparation of Ehrlich's Hematoxylin solution

Hematoxylin crystals	4.0 g
Alcohol, 95%	200.0 ml
Ammonium or potassium alum	6.0 g
Distilled water	200.0 ml
Glycerine	200.0 ml
Glacial acetic acid	20.0 ml

Hematoxylin is dissolved in the alcohol and the alum is dissolve in distilled water and mixed thoroughly. After these are in complete solution the glycerin and acetic acid are added.

□ Preparation of eosin solution

1% stock alcoholic eosin

Eosin Y, water soluble	1 g
Distilled water	20 ml
95% alcohol	80 ml

Eosin was dissolved in water and then 80 ml of 95% alcohol was added.

Working eosin solution

Eosin stock solution	1part
Alcohol, 80%	3 parts

0.5ml of glacial acetic acid was added to 100 ml of working eosin solution just before use.

3.4.2.4 Staining protocol

The sectioned tissues were stained as described bellow:

- ❖ The sectioned tissues were deparaffinized in three changes of xylene (three minutes in each)
- ❖ Then the sectioned tissues were rehydrated through descending grades of alcohol as per following schedule.
 - Absolute alcohol - three changes (three minutes for each)
 - 95% alcohol - two minutes
 - 80% alcohol - two minutes
 - 70% alcohol - two minutes
 - Dipping with distilled water for 10 minutes.
- ❖ The tissues were stained with Harris hematoxylin for 2-10 minutes.
- ❖ Washed in running tap water for 10-15 minutes.
- ❖ Then the tissues were dipped in ammonia water (few dips).
- ❖ Stained with eosin for one minute.
- ❖ Differentiated and dehydrated in ascending grade of alcohol.
 - 95% alcohol - three changes (2-4 dips for each.)
 - Absolute alcohol - three changes (2-3 minutes for each)
- ❖ Cleaned in xylene: three changes (five minutes each).
- ❖ Tissues were mounted with cover slip by using DPX

The slides were dried at room temperature and examined under a low (10X) and high (40X, 100X) power objectives.

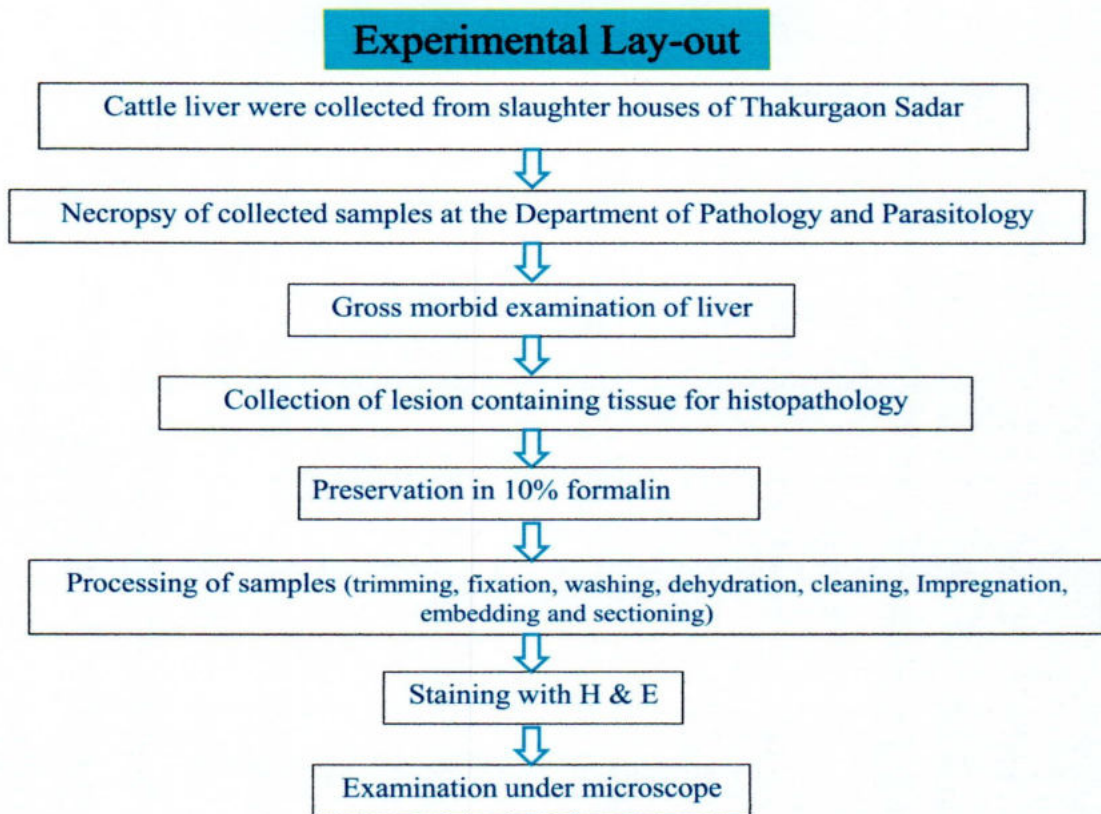


Figure 1: Schematic illustration of the experimental layout

A large, semi-transparent red ribbon graphic is centered on the page. It has a central rectangular section and two larger, trapezoidal sections extending outwards to the left and right, creating a wide, decorative banner effect.

CHAPTER IV

RESULTS

CHAPTER IV

RESULTS

The number of 64 diseased livers are collected from different slaughter house are subjected for gross & microscopic examination. Grossly the liver shows abnormality in its parietal and visceral surface and microscopically the liver show abnormalities in normal architecture. The disease or disorders are shown in Table 1. The infection of fascioliasis shown highest 44 (68.75%) among 64 diseased livers examined, followed by hydatidosis 15 (23.43%), cirrhosis 8 (12.5%), abscess 4 (6.25%) and mixed infections 5 (7.81%).

4.1 Fascioliasis

In 64 diseased livers examined, 44 (68.75%) were found to be affected with liver fluke, *Fasciola gigantica*. Of these 44 *Fasciola* affected livers 24 (54.5%) belonged to female and 20 (45.5%) belong to male cattle. Six livers affected with fascioliasis exhibited mixed infection with either of hydatidosis or cirrhosis also occurred. In sub-acute and chronic infections. Two forms of fascioliasis were recorded in period of investigation

4.1.1 Gross changes

In acute form, the colour of liver become paler than normal chocolate colour & it also slightly swollen or enlarged with rounded edges, which occurred in two year to eight years ages of animal. The capsule was more or less thick, opaque and rough. In the parietal surface of the right lobe where light hemorrhagic spots or elongated tracks with numerous swelling and round shapes are found. The affected organ is also soft in consistency (Fig.1).

In some chronic cases, the size of livers are reduced with irregular and granular appearance. In some cases, the different size of hepatic nodules are found which shapes separated by invading tracks of fibrous connective tissue were distinctly seen. Such livers were soft in consistency and hard to cut. The capsule was thick

and opaque. The whitish fibrosis also found in left lobe & the periphery of the caudate.

4.1.2 Histopathologic changes

In the zone of reaction the ruptured. Blood vessels were highly congested. In some sections, the centre of the lobe contained a mass of degenerating neutrophils which were thought to be the part of a migrating immature flukes. The destruction of the hepatic cord, extra vascular erythrocytes are also seen (Fig-2). The, hepatic necrosis along with reactive cells infiltration are found . the hepatic parenchyma also abnormal.

In chronic cases the hemorrhagic tracks or tunnels were represented by the areas infiltrated with fibroblasts, neutrophils, lymphocytes and mononuclear cells. In many sections, the lobular architectures were found to be distorted by heavy accumulation of lymphocytes and proliferation of fibrous connective tissue in the portal area. In some cases, fibrous connective tissue penetrated into the parenchyma of the lobules. Due to fibrosis many portal lobes were observed to be closer to each other, where the normal lobular architecture is destructed.

4.2 Hydatidosis

Among 64 livers where fifteen (15) of disease livers (23.43%) were found to be affected with hydatid cyst. Among them nine (5.76%) were from female and six (3.84%) from male cattle. Mixed infection associated with hydatidosis & fasciolosis also found in four liver affected with hydatidosis.

4.2.1 Gross changes

The cysts were found both of the parietal and visceral surfaces of the left, right and caudate lobe. Most of the cysts were situated superficially just beneath the capsule, mainly at the dorsal part of the right lobe (Fig- 3). The cyst filled with fluid & covered by layer of connective tissue.

The colour of the livers was white glistening in some cases but exhibit almost normal colour. Some dark haemorrhagic spots were noted in the parenchyma of

the liver adjacent to the cyst. The parenchyma around the cyst seemed to be hard and fleshy. The liver capsule becomes thicker over the cyst.

4.2.2 Histopathologic changes

The central vein are dilated around the cyst. The blood vessels of the central vein were congested. The sinusoids were dilated & engaged with blood vessel (Fig. 4). The hepatic cord distended. In some cases, profuse leukocytic infiltration are found, where hepatocytic loss and obliteration of cords are also found. The normal architecture of the lobules around the cyst was distorted in most of the cases. The inner most nucleated layer containing one layer of cells was seen to project inwards to form blood capsule. The middle laminated stained dark reddish due to presence of chitin or keratin. The infiltration of eosinophils, macrophages are also found.

4.3 Cirrhosis

A total of 8 cases (12.5%) showed partial or complete cirrhosis. Among them five (3.2%) of female and three (1.92%) of male cattle were affected with cirrhosis.

4.3.1 Gross changes

The color of the liver was pale or whitish gray. The livers are hard and leathery in consistency. It was tough to cut with scissors (Fig-5). In most of the cases adult flukes were recovered. The liver was contracted in many cases sinks into water. It was observed that the migration of only one or two adult liver fluke could initiate liver cirrhosis. The capsule was wrinkled. Sometime there was found whitish spots, slightly depressed were focally distributed in the parenchyma of the liver. The spots were hard and firm, tough to cut through incision and on pressure nothing was found to come out from the spots.

4.3.2 Histopathological changes

In the portal area considerable proliferation of fibrous connective tissue were found. There were a few lymphocytic infiltrations in the fibrous strands (Fig-6). The portal vein becomes dilated and irregular in shape. The proliferating fibrous

tissue progress to the interlobular spaces, as a result the individual lobules were squeezed. Due to squeeze the haemorrhagic dot are found in the lobular space. The degenerative hepatic cells were also found as necrotic foci where lymphocytes and mononuclear cells are infiltrated.

4.4 Abscess

Abscess was found in only four cases (6.25%). Abscess liver was mainly found in female cattle. Where three (1.92%) are female & one (0.64%) male.

4.4.1 Gross changes

The whitish or yellowish foci are found in the surface of the liver (Fig-7). One of the containing liver pyogenic lesions was also associated with fascioliasis. The foci of abscess were odorless. The abscess filled with creamy exudates.

4.4.2 Histopathological changes

Histopathological changes were characterized by the hepatic destruction with obliteration of hepatic cords. The normal architecture of hepatic lobules are destructed. The presence of polymorpho nuclear leukocytes at the centre surrounded by a thin fibrous capsule. Fibrous thickening of the liver capsule and moderate infiltration lymphocytes, mononuclear cells and pus cell were found, (Fig-8).

4.5 Mixed infection

Mixed infection was characterised by the presence of three or more diseases of which five livers (7.81%) were affected with Fascioliasis, Hydatodiasis and Cirrhosis (Fig. 9). Along with Fasciola there found two livers with Hydatidosis and one liver with Cirrhosis. Among five affected livers, 3 (1.92%) are male & 2 (1.28%).

4.5.1 Gross changes

In gross changes all the changes observed in mixed infection were similar to the lesions described earlier in the individual disease. Apart from these two to three

nodular structures. In diameter were found on the medial surface of the left lobe along with the course of bile ducts and blood vessels. On incising, the nodules showed laminated areas with caseous mass which was yellowish in colour. Sometime there found calcified mass in the liver.

4.5.2 Histopathologic changes

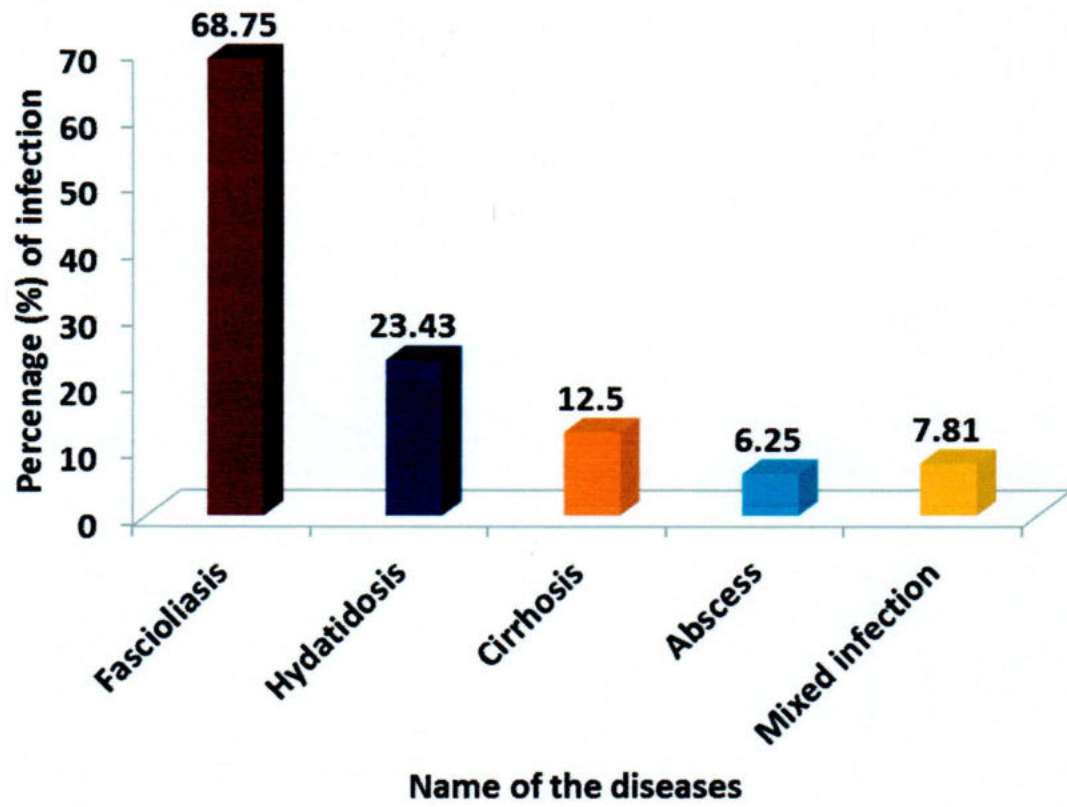
In microscopical changes, these areas were containing a large reserve of blood circumscribed by fibrous connective tissue. Cellular infiltrations with some fibrous connective tissue are seen. In some cases irregular tunnels or tracts originating from the portal area and also from the central vein extended to the parenchyma causing destruction of hepatic cells. These tunnels and tracts were surrounded by slight fibrosis and might be due to migration of parasite calcification was found in the hyperplastic bile ducts epithelium.

Table A. Number of disease found during the investigation period from January 2014 to June 2014.

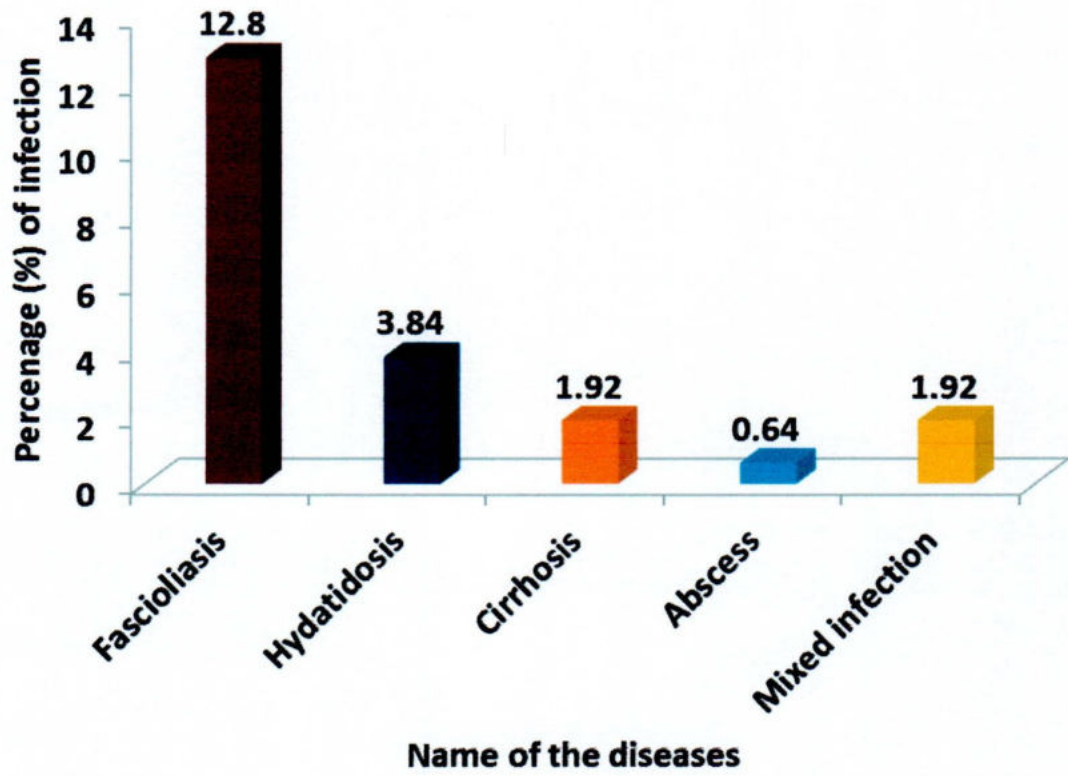
Disease /Disorder	No of Diseased liver examined	Number affected	% of Infection	Remarks
Fascioliasis	64	44	68.75	6 cases associated with Hydatidosis & Cirrhosis.
Hydatidosis	64	15	23.43	4 cases associated with Fascioliasis
Cirrhosis	64	8	12.5	2 cases associated with Fascioliasis
Abscess	64	4	6.25	—
Mixed Infection	64	5	7.81	Associated with Cirrhosis, Fascioliasis, Hydatidosis
Total pathological conditions	64	76		

Table B. Showing distribution of the pathological conditions in relation to sex

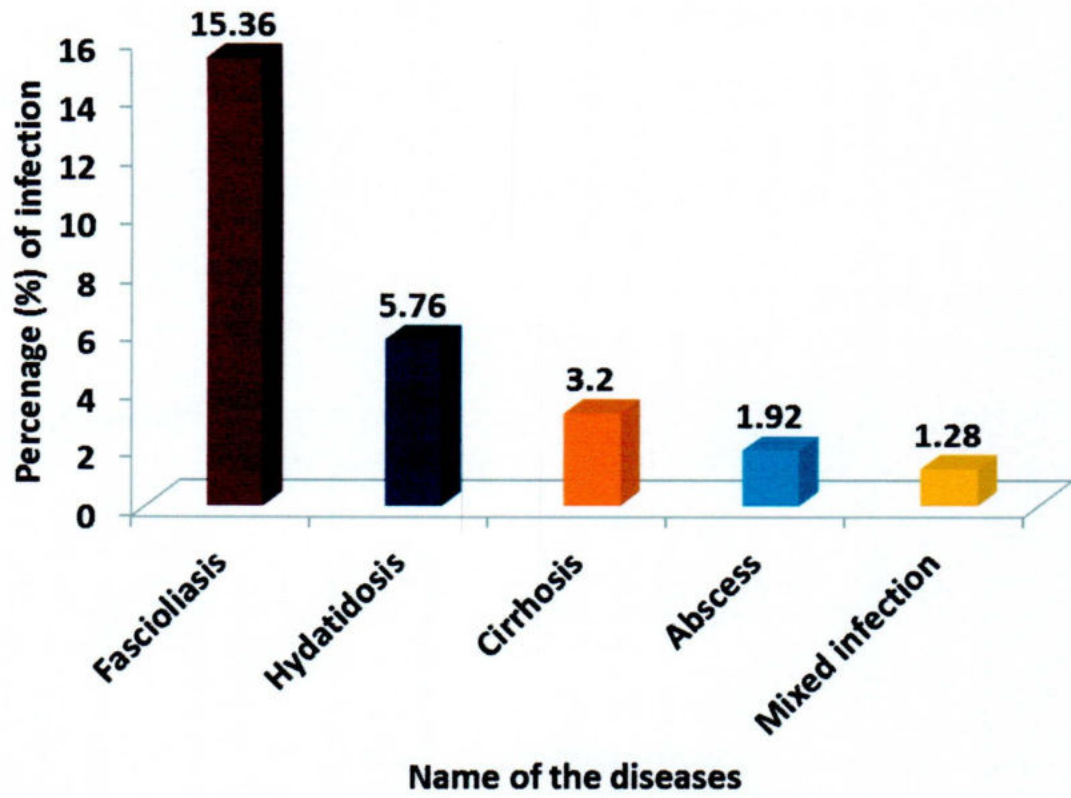
Disease /Condition	No. of animals affected	No. of male affected	Percentage of male affected (%)	No. of female affected	Percentage of female affected (%)
Fascioliasis	44	20	12.8	24	15.36
Hydatidosis	15	6	3.84	9	5.76
Cirrhosis	8	3	1.92	5	3.2
Abscess	4	1	0.64	3	1.92
Mixed Infection	5	3	1.92	2	1.28



Graph 1: Graphically representation of different disease condition



Graph 2: Graphically representation the ratio of male in different disease condition.



Graph 3: Graphically representation the ratio of female in different disease condition.

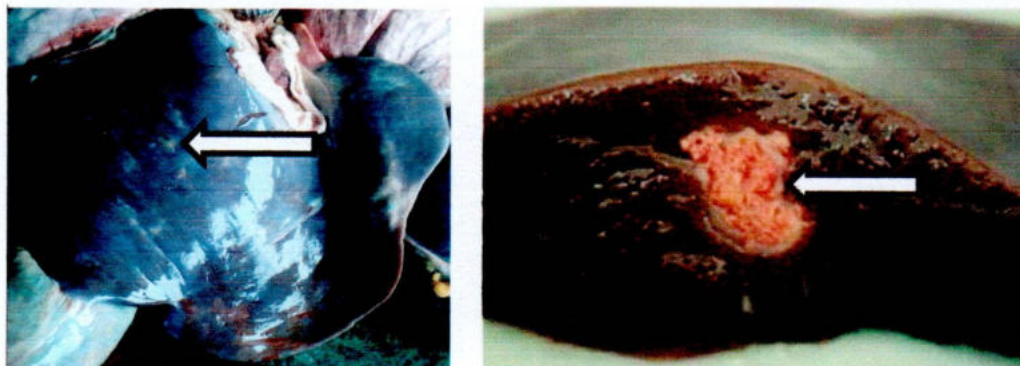

Fig. 1: Fascioliasis affected hepatic areas (Fibrotic area).

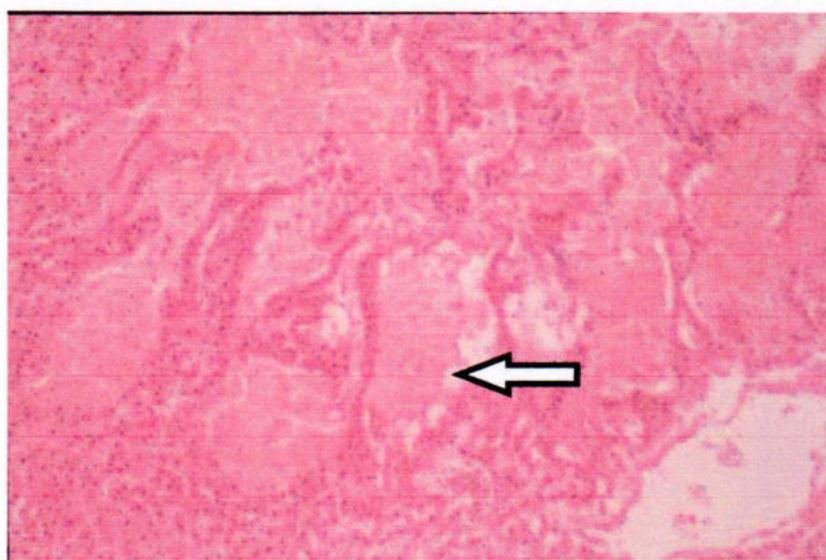

Fig. 2: Destruction of hepatocytes and extravascular erythrocytes

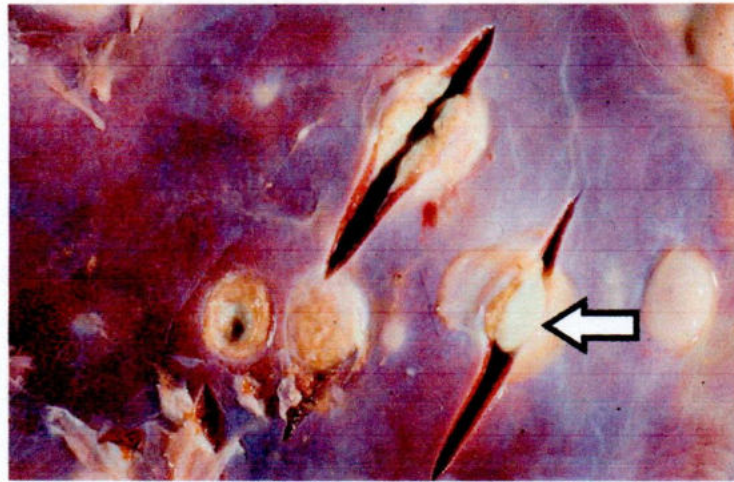


Fig. 3: Hydatidosis (caseating sports with dystrophic calcification).

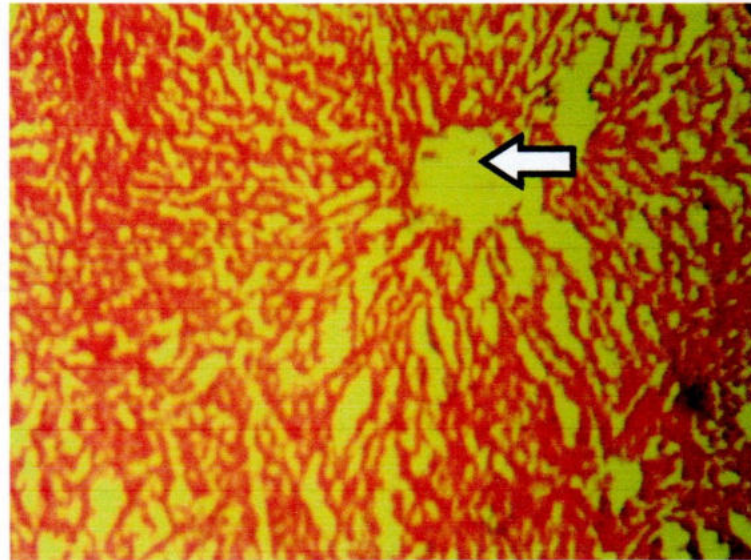


Fig. 4: Distended cords with dilated central vein

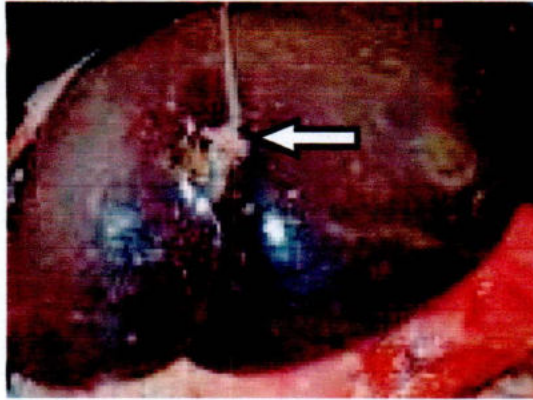


Fig. 5: Cirrhosis (Focal necrotic area, whitish spots)

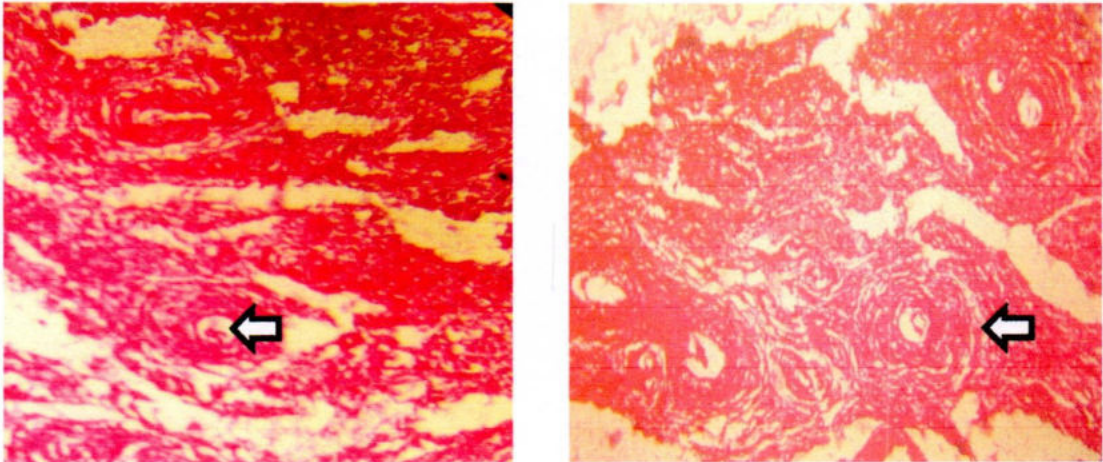


Fig. 6: Proliferated Fiber Connective Tissue with the pre-existing hepatic cells

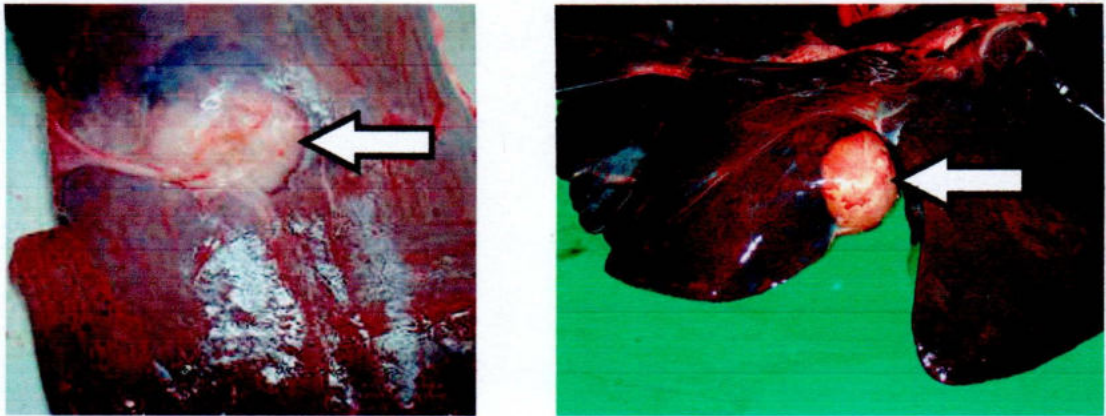


Fig. 7: Abscess filed up with creamy exudates

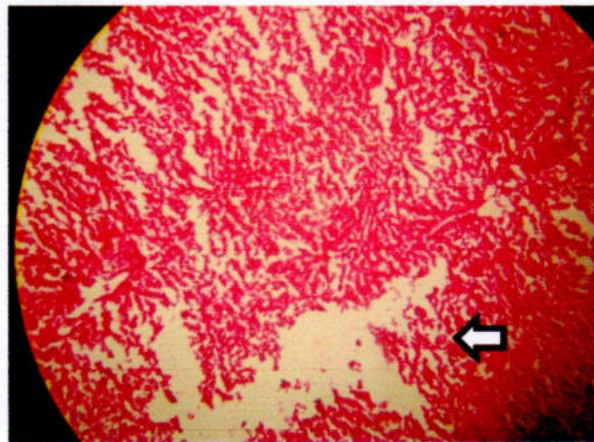


Fig. 8: Hepatocytic destruction with obliteration of hepatic cords as well as architecture structures of hepatic lobules

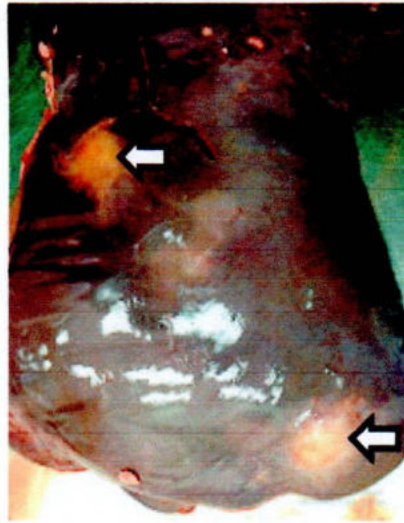
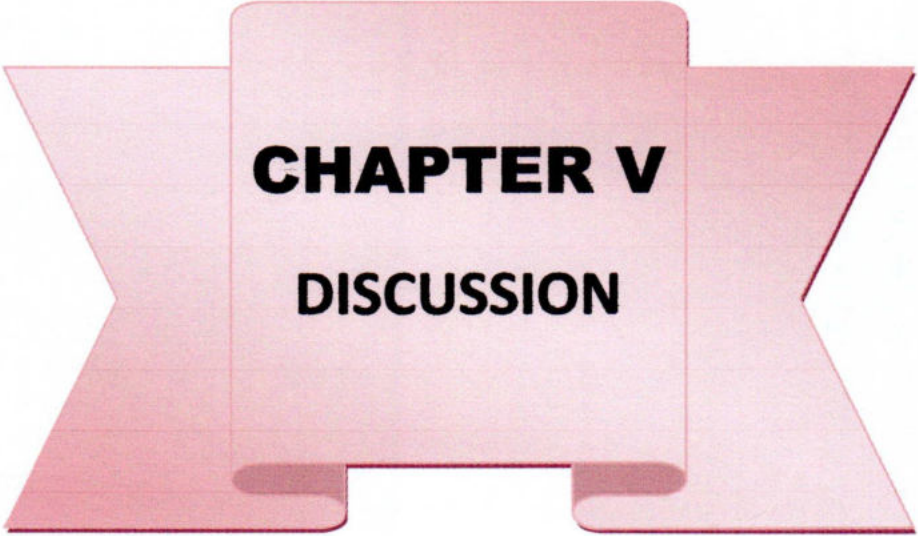


Fig. 9: Mixed infection (Mass fibrotic area)



CHAPTER V

DISCUSSION

CHAPTER V

DISCUSSION

The objective of this study was to find out the outbreak of various types of diseases affecting liver of cattle in Thakurgaon sadar of Bangladesh. The inspection carried out in the slaughter house of Thakurgaon sadar. The period of this inspection from 1st January, 2014 to 30th June, 2014.

5.1 Fascioliasis

Samples both of the sexes of adult cattle are collected, Any sex variations of infection are recorded where various diseases are included. The samples are collected randomly. There was no difference in prevalence between males and females. The same inspection was also recorded by Bindernagel (1973). Therefore, the seasonal variation could also be obtained in different parasitic diseases. Phiri *et al.* (2005) reported seasonal variation of *Fasciola gigantica* and the pattern of distribution of *F. gigantica* was significantly higher in areas of high rainfall than in those of relatively low rainfall.

Among 64 examined livers, the infection of fascioliasis occurred in 44 (68.75%) livers. Studies on *Fasciola* infections in live animals, reported the prevalence of 56.5% in Arusha which is in northern Tanzania (Swai *et al.*, 2006). Examination of livers of 4620 domestic animals from south east Iraq indicated that 20.5% of all animals were infected with *Fasciola gigantica* and/or *Fasciola hepatica*. This has been reported in 1973 by Shaba *et al.* The infection rates were 91.4% for buffaloes, 49.2% for cows, 29.0% for sheep and 11.2% for goats. The gross and microscopic changes which produced by *Fasciola gigantica* infection were almost similar with the earlier findings (Dow *et al.*, 1967, Soulsby, 1982 and Dhote *et al.*, 1992). The hemorrhagic tracts on the parenchyma of liver could be the indication of transperitoneal route of migration of young flukes. The damage of hepatic cells near these tracts might have resulted from feeding habit of these premature

parasites (Sengupta and Iyer, 1968). In cross section of liver there found pipe stem appearance of the liver caused by the migration of the parasites. Ansari-Lari and Moazzeni (2006) reported more or less same result on the prevalence of liver condemnations due to fascioliasis. Predominancy of the occurrence of fascioliasis as a single infection as seen in this study contradicts an earlier report By Trifonov (1980) who recorded a predominance of mixed infection in sheep liver in Bulgaria. Like Roberts (1968), Acosta-Ferreira, *et al.*, (1980). And Sengupta and Iyer (1968), both acute and chronic forms of fascioliasis have been detected in the present study. The gross pathological changes in acute fascioliasis described by these authors may be summarized as light haemorrhagic spots or elongated tracked occurring on the surfaces of the liver.

The microscopical changes in chronic cases characterized by the filtration of leukocyte and fibroplasia in the area previously migrated by young flukes. Similar statement was made by Smith *et al.*, (1972). Heavy accumulation of lymphocytes and proliferation of fibrous connective tissues in the portal areas are seen. There were hyperplastic changes of the epithelial cells of the bile ducts with periductal connective tissue proliferation were found. In most advanced stages these hyperplastic bile ducts appeared like granular structures as recorded in the study of Upadhyay *et al.* (1987). Hepatic siderosis (Gupta, 1982) was also observed in this study. Formation of blebs at the free margin of the epithelial cells undergoing hyperplasia was a common picture. Most advanced stages hyperplasia led to the formation of gland-like structures. The mucosa was often infiltrated with plasma cells and few eosinophils. Formation of new bile ducts and deposition of bile pigment in the tissue spaces were seen. These findings substantiated the observations of Stenius (1963), Dawes (1963) Acosta-Ferreira *et al.*, (1980), Ross (1966), Ross *et al.*, (1967), Dow *et al.*, (1967) and Smith *et al.*, (1972). Similar to the finding of Dow *et al.*, (1967) and Rahko (1969), thrombi were found in the blood vessels. In this study there were found calcification in the wall of bile ducts of the liver in chronic fascioliasis in cattle. Similarly, according to Ross, 1966 and Dow *et al.*, 1967 there found calcification in cattle,

contrary to findings according to Simensen (1968) and Pullan *et al.*, (1970), says the bile ducts of the liver in sheep never calcified.

5.2 Hydatidosis

Among 64 liver hydatidosis has been detected in fifteen livers. Among them six (40%) were from male and nine (60%) from female cattle. Here we found among 64 affected livers there found 23.43% liver (fifteen livers) affected. This statement support Sheikh and Hussain (1968), who recorded that 35% buffaloes were infected with hydatid cysts in Bangladesh, but a higher prevalence of hydatidosis (60.6%) has been reported from Sheikh *et al.*, (1983) found in Bangladesh. Higher prevalence has been attributed to a frequent contact between the intermediate and the final host in this area. Multiple cysts found in most of the cases. Some affected livers were found with severe damage of the parenchyma. The size of hydatid cysts varied from 0.5 to 20 cm. in their greatest dimension and the examined cysts were sterile. This finding supports the work of Soulsby (1969) but contradicts the work of Verster (1961) who found large number of fertile cysts in the liver of cattle. Present study showed that the hydatid cyst consisted of 3 layers which were also reported in the observation of Cameron and Webster (1969). Moreila *et al.*, (1983) recode that 7.43% male and 12.35% female cattle were infected with hydrated cysts. The present study also revealed variation in male (38.46%) and female (61.54%) cattle, which is similar to Monirul (1993) that shows the variation in male (37.1%) and female (62.82%) buffaloes.

In three cases, the liver was found severely damaged with hydatid cyst. This was also found by Mamedov (1965). Around the hydatid cyst there was marked cellular reaction characterized by proliferation of fibroblasts, infiltration of mononuclear cells and eosinophils as reported earlier by Dhote *et al.*, (1992).

5.3 Cirrhosis

In cirrhosis 8 cases (12.5%) are almost equally distributed in male and female where partial or complete cirrhosis detected . Mixed infection associated with

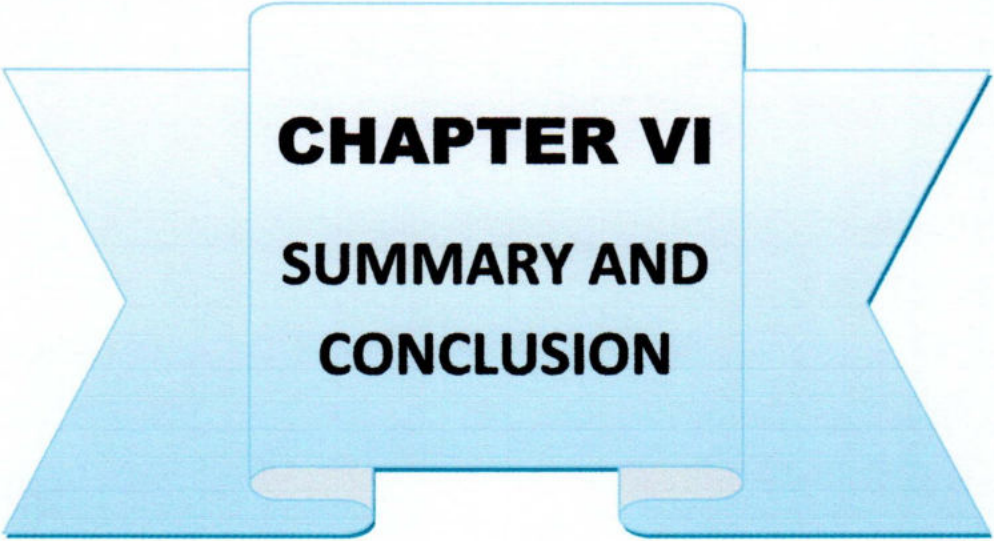
fascioliasis & cirrhosis are found in most cases. Therefore, it may be opined that fascioliasis is one of the most important causes of cirrhosis in cattle in this country. The liver was constricted in many cases. Numerous newly formed bile ducts in cirrhotic liver have been observed in the present study as described by previous researchers (Gupta, 1983; Khalilov and Namosov, 1983). Considerable proliferation of fibrous connective tissue was marked mainly in the portal area. There was little lymphocytic infiltration of fibrous strands. The dilation of Portal veins occurred which become irregular in shape.

5.4 Abscess

It is supposed the entrance migration of immature flukes are main reason of the hepatic abscess. The hepatic abscess are not calcified in this study. Such as hypothelial statement has also been made by Salo *et al.*, (1978), Elmoosalami and Darweish (1977) and Uzoukwu and Ikeme (1978). In this study abscess was found in only 3.85% cases, which is similar to that of Ahmedullah *et al.*, (2007). Grossly, whitish foci on the surface of the liver were found. Size varied from 0.5 to 1.5 cm in diameter. Polymorphonuclear leukocytes at the center surrounded by a thin fibrous capsule were seen microscopically. According to Runnels *et al.*, (1976), hepatic abscess may or may not calcify. In the present study the hepatic abscess did not calcify.

5.5 Mixed Infection

Mixed infection associated with Fascioliasis and Hydatodiasis and Cirrhosis are observed in five liver. Three livers with Cirrhosis and one liver with Fascioliasis and one liver with Hydatodiasis were seen. The remarkable low infection of *Fasciola gigantica* occurred in cirrhosis.



CHAPTER VI
SUMMARY AND
CONCLUSION

CHAPTER VI

SUMMARY AND CONCLUSION

In the slaughter house of Thakurgaon sadar 64 abnormal cattle liver are collected for pathological investigations with a view to exposing different kind of disease conditions affecting the liver of cattle.

During the course of this study, 44 (68.75%) liver affected samples are collected. The causal agent is, *Fasciola gigantica*. Of these 44 *Fasciola* affected livers 20 (12.8%) belonged to male and 24 (15.36%) belong to female cattle. 15 of hydatidosis disease livers (23.43%) were found to be affected with hydatid cyst. Among them six (3.84%) were from male and nine (5.76%) from female cattle. A total of 8 cases (12.5%) showed partial or complete cirrhosis. Among them three (1.92%) of male and five (3.2%) of female cattle were affected with cirrhosis. Abscess was found in only four cases (6.68%). Abscess liver was mainly found in female cattle. Along two livers with Cirrhosis one liver with Fascioliasis and one liver Hydatidosis with were found. In mixed infection five cattle are affected, where three (1.92%) are female & two (1.28%) are male.

Both gross and histopathological features of each of the above disease have been described.

On the basis of the findings in this study the following conclusions may be drawn:

1. Livers of cattle are mostly affected with parasitic diseases such as fascioliasis, hydatidosis and cirrhosis.
2. Fascioliasis (*Fasciola gigantica*) is greatly responsible for hepatic damage.
3. Female species were found to be frequently affected with hydatidosis than male species. Hydatidosis recorded in male and female species 40% and 60%, respectively.

4. Mixed infections were represented by more than one type of infection, which was found increased with the advance of ages.
5. The high rate of infection in rainy season is quite reasonable. During this time the rainfall is abundant and there is abundance of intermediate hosts of Fasciola.



REFERENCES

REFERENCES

- Acosta-Fereira, W., Vercelli-Ratta, J. and Falconi, L. M. (1980). *Fasciola hepatica* human infection, histopathological study of 16 cases. Helm. Abstr. 49(4): No.1555 (1980).
- Ahmed A.M.Ismail.S.A.S and Dessouki A.A. pathological lesions servey & economic loss for male cattle slaughtered at Ismail abattoir,International food research journal 20(2);857-863(2013).
- Ahmedullah, F., Akbor, M., Haider, M. G. and Hossain, M. M. (2007). Pathological investigation of liver of the slaughtered buffaloes in Barisal district. Bangl. J. Vet. Med. (2007). 5 (1 & 2): 81-85.
- Al-Abbassy, S. N., Altaif, K. I., Jawad, A. K. and Al-Saqur, I. M. (1980). The Prevalence of hydatid cysts in slaughtered animals in Iraq. J.Helm. 74(2); 158-187.
- Al-Barwari, S. E. (1977). A survey on liver infections with *Fasciola gigantica* among slaughtered animals in Iraq. Helm. Abstr. 48: 4306.
- Al-Yaman, F. M., Assaf, L., Hailat, N. and Abdel-Hafez, S. K. (1985). Prevalence of hydatidosis in slaughtered animals from North Jordan. 985 Oct; 79(5):501-6.
- Ansari-Lari, M. and Moazzeni, M. (2006). A retrospective survey of liver fluke disease in livestock based on abattoir data in Shiraz, south of Iran. Preventive Vet Med 73 (1): 93-96.
- Anwar, A. H., Shamim, H. R., Khan, M. N. and Qudoos, A. (2000). Hydatidosis: Prevalence and biometrical studies in cattle (*Bos indicus*). Pak. J. Agri. Sci. Vol. 37(1-2).

- Anwar-Ul-Haq. (1994). Economic significance, biometry and chemical composition of hydatid cyst in cattle (*Bos indicus*) Pub. 1994 Pp.131.
- Asdrubali, G. and Mughetti, L. (1966). Changes in the gall bladder of cattle with fascioliasis. *Atti.soc. ital.sci.vet.*20: 553-557.
- Ashizawa, H., Nosaka, D. and Osato, K. (1966). Epidemiology of fascioliasis in pigs in southern kyusyu. *Ibid.* 12:58-79.
- Atasever, A., Vural, S.A. and Berkn, S. (2002), Incidence and pathological studies on liver telangiectasis in beef cattle. 26(2): 235-238.
- Balasingam, E. (1962). Studies on fascioliasis of cattle and buffaloes in Singapore due to *Fasciola gigantica*. *Ceylon Vet Jour* 10: 10-29.
- Bettini, G. and Marcato, P. S. (1992). Primary hepatic tumours in cattle. A classification of 66 cases, Vol 107, Issue 1, Pp 19-34.
- Bhuyan, M. H. (1970). A survey of helminths parasitizing the liver of domesticated ruminants in East Pakistan. M.Sc. (Vet. Sc.) Thesis, department of parasitology. East Pakistan Agril. Univ., Mym, Bangl.
- Bindernagel, J. A. (1973). Liver fluke *Fasciola gigantica* in African buffalo and antelopes in Uganda, East Africa. *J. Wildlife Dis.* 8(4); 315-317. *Vet. Bull* 1973 43, 2155.
- Bostelmann, S. C. W., Luz, E., Soccol, V. T. and Cirio, S. M. (2000) Hepatopathology of infection by *Fasciola hepatica* in cattle, buffaloes and sheep. *Vet-Sci.* 2000; 5: Pp 95-100.
- Cameron, T. W. M. and Webster, B. A. (1969). The histogenesis of the hydatid cyst (*Echinococcus spp.*) part-I, Liver cysts in large animals. *Can. J. Zool.* 47(6): 1405-1410.
- Chen, M. G., (1991). *Fasciola hepatica* infection in China. *Chinese Academy of Preventive Medicine, Shang.* 991 Dec; 22 Suppl: 356-60.

- Dawes, B. (1963a). Hyperplasia of the bile duct in fascioliasis and its relation to the problem of nutrition in the liver fluke *Fasciola hepatica*. L. Parasitology, 53(1/2): 123-133. Helm. Abstr. 33 (1): No. 450. (1964).
- Dhote S. W., Ingle A. D., Bhandarkar, A. G., Joshi, M. V. and Bhagwat, S. S (1992). Hepatic Lesions in Buffaloes. Indian J. Vet. Path. 16(1):42-44.c
- Dow, C. Ross, J. G and Todd, J. R. (1967). The pathology of experimental fascioliasis in calves. Jour. of comparative Path. 77: 377-385.
- Dow, C., Ross, J. G. and Todd, J. R. (1968). The histopathology of *Fasciola hepatica* infection in sheep. Parasitology, 58(1): 129-135
- Elmossalami, E. and Darweish, A. (1977). Microbiological investigations in Denmark. Diagnostic examination of bovine feces over 15 years. Helm. Abstr. 49 (4): no. 3971(1980).
- Ghosh, R.K. (2006). Primary Veterinary Anatomy, Current Books International, Kolkata, 4th edition : Pp. 202-203.
- Gupta, P. P. (1981). A note on inclusion body hepatitis in buffalo calf. Indian Vet. J. 58(12):995.
- Gupta, P. P. (1982). Hepatic siderosis in Indian buffaloes. Indian. Jour. of Ani. Sci. 52: 1185-1188.
- Gupta, P. P. (1983). Studies on pathology of buffaloes livers. Indian Jour. of Vet. Path. 7: 91.
- Hammond, J. A. (1972). Infections with *Fasciola* spp. Wild life in Africa. Tropical animal Health & Production. 1972:4(1): 1-13. Vet. Bull.42:4684.
- Hammond, J. A. and Sewell, M. M. H. (1990). Diseases caused by helminthes. In: M M H Sewell and D W Brocklesdy Handbook on Animal Diseases in the Tropics, 4th edition. CTVM. Edinb. Uni. pp 119-123.

- Haroun, E. M. and Hussein, M. F. (1975). Clinico-pathological studies on naturally-occurring bovine fascioliasis in the Sudan; *Jour. of Helminth* (1975), 49:143-152.
- Iqbal, Z., Hayat, C. S., Hayat, B. and Khan, M. N. (1989). Prevalence, organ distribution and economics of hydatidosis in meat animals at Faisalabad abattoir. *Pak. Vet. J.* 9: 70-74.
- Irfan, M. and Lee, R. P. (1968). Pathology of the liver in ovine fascioliasis before and after treatment. *Ir. Vet. J.* 22(10): 182-190.
- Islam, F. M. S., M. H. Rahman and S. M. Z. H. Chowdhury, (1992). Prevalence of parasites of water buffaloes in Bangladesh. *Asian Austr. J. Anim. Sci.*, 5: 601-604.
- Jampolsy, B.V. (1979). Influence of hydatidosis on quality of beef production. *Visnyk sel's kohospidars Koi nauki, Kygiv.* 9: 64-65. *Helm. Abstr.* 49(9):3971.
- Johnson, E. H., Muirhead, D. and Gerard, J. K (1999). An Abattoir Survey of Caprine Liver Diseases in the Sultanate of Oman; November 1999, Vol 158 Pp 216-220.
- Kakar, M. N. and Kakarsulemankhel, J. K. (2008). Prevalence of endo (trematodes) and ecto-parasites in cows and buffaloes of quetta., *Pak. Vet. J.*, 2008, 28(1): 34-36.
- Kale E. Akpabio U and Gloria D.I.(2015) A case of chronic fasciolosis in a cattle slougtered at ubakala abattoir, *Jouurnal of veterinary advances.* 5(6):1017-1022.
- Kendal, S.B. (1954). Fascioliasis in Pakistan. *Ann. Trop. Med. Parasit.* 48:Pp 307-313.

- Khan, M. K., Sajid, M. S., Khan, M. N., Iqbal, Z. and Iqbal, M. U. (2008). Bovine fasciolosis: Prevalence, effects of treatment on productivity and cost benefit analysis in five districts of Punjab, Pakistan. Vol. 87, Issue 1, Pages 70-75.
- Kim-YeonSoo, Kim-SangKyun, Hwang-EuiKyung (2000). Prevalence of fascioliasis in Korean native cattle in the Kangwon province of Korea. *pub. 41(4)* Pp 557-563.
- Luna, L.G. (1968). *Manual of Histologic Staining Methods of the Armed Forces Institute of Pathology*. 3rd edn., MC Graw Hill Book Co, New York.
- Magzoub, M and Kasim, A. A. (1978). The prevalence of Fasioliasis in Saudi Arabia. *Helm. Abstr. 1979. 48(4): 1625.*
- Malaki, A. and Mahiyuddin, S. (1970). Obliterating endophlebitis of hepatic veins in Indian buffalos (Budd Chiari syndrome disease). *Indian vet. J. 47 (6): 469-471.*
- Malik, M. R., Prakash, P. (1972). A quantitative histological study of the liver of buffalo (*Bubalus bubalis*) and Ox (*Bos indicus*). *J. Anatom. Soc. India. 21(3): 131-133. (Vet. Bull. 1974. 44: 2583).*
- Mamedov, A. K. (1965). Exceptionally high hydaitid infection of the liver in a buffalo cow (abstract) *veterinariya 42(4): 51-52. (Helm. Abstr. 1967.36: 61).*
- Menkir, M. S., Uggla, A. and Waller, P. J. (2007). Prevalence and seasonal incidence of nematode parasites and fluke infections of sheep and goats in eastern Ethiopia, *Tropical Animal Health and Production 39(7): 521-531.*
- Monirul, A. K. M. (1993). *Pathology of the buffalo liver. Bangladesh agricultural university. Mymensingh. 1993: 51-55.*



- Munir, M. A. (1980). Incidence of hydatidosis in ruminants at Faisalabad abattoir and chemical characterization of the cyst fluid in buffalo. M.Bc. Thesis, Univ. Agri., Faisalabad.
- Mwabonimana, M. F., Kassuku, A. A., Ngowi, H. A., Mellau, L. S. B., Nonga, H. E. and Karimuribo, E. D. (2008). Prevalence and economic significance of bovine fasciolosis in slaughtered cattle at Arusha abattoir, Tanzania. *Tan. Vet. Jour.* Vol. 26, No. 2 2009.
- Nabil A.M. Salmon, Snur M.A. Hassan Azad K Saeed (2013). Histopathological study of chronic livers fasciolosis of cattle in sulaimini abattoir, Al-Quidiya journal of vet. med. science vol 13 - no.2
- Nagaraja, T. G., Lechtenberg, K. F. (2007). Liver abscesses in feedlot cattle. *Veterinary-Clinics-of-North-America,-Food-Animal-Practice.* 2007; 23(2): 351-369.
- Nagarajan, B., Vijayanand, V., Srinivasan, S. R. and Nambi, A. P. (2007). Fatty liver syndrome in cattle. *Indian-Veterinary-Journal.* 2007; 84(12): 1334.
- Pal, R. A. and Jamil, K. (1986). Incidence of hydatidosis in goats, sheep and cattle. *Pak. Vet. J.* 6 :69-85.
- Phiri, A. M., Phiri, I. K., Sikasunge, C. S. and Monrad, J. (2005). Prevalence of fasciolosis in Zambian cattle observed at selected abattoirs with emphasis on age, sex and origin. *Jour. Vet. Med. B. Infectious Diseases of Vet. Pub. Heal.* 52 (9): 414-416.
- Prasad, N.B. Mondal, L.n. (1980). Hydatidosis in goat in India. *Philippine J. Vet. Med.* 17(1/2): 191-196. *Helm. Abstr.* 1980. 49(3):1053.
- Pullan, N.B., Sewell, M. M.H. and Hammond, J.A. (1970). Studies on the pathogenicity of massive infections of *Fasciola hepatica* in lambs. *Helm. Abstr.* 40(2): 2267(1971).

- Rahko, T. (1969). The pathology of natural *Fasciola hepatica* infection in cattle. Helm. Abstr. 40(2) : No. 2270(1971).
- Regassa, F., Molla, A. and Bekele, J. (2009). study on the prevalence of cystic hydatidosis and its economic significance in cattle slaughtered at Hawassa Municipal abattoir, Ethiopia; Vol 42, Number 5 / June, 2010, Pp 977-984.
- Roberts, H. E. (1968). Observations on experimental acyte fascioliasis in sheep. Br. Vet. J. 124(10): 433-450.
- Ross, J. G. (1970). The economics of *Fasciola. Hepatica* infections in cattle. Br. Vet. J. 126(4): 13-15. [Helm. Abstr. 1971.40(1): 846].
- Ross, J. G. 1966. An Abattoir survey of cattle liver infections with *F. hepatica*. Br.Vet. J. 122(11): 489-494.
- Ross, J. G. and Dow, C. (1966). The problem of acute fascioliasis in cattle. Vet.Rec. 78: 670.
- Ross, J. G., Dow, C. and Todd, J. R. (1967). The pathology of *Fasciolia hepatica* infection in pigs: A comparison of the infection in pigs and other hosts. Br. Vet. J. 123 (7): 317-322.
- Runnels, R. A., Monlux, W.S. and Monlux, A.W. (1965). Principles of Veterinary Pathology. &the din. Scientific Books Agency, Calcutta. Pp.644-648.
- S. A. Sardar, M. A. Ehsan, A. K. M. M. Anower, M. M. Rahman and M. A. Islam (2003). Incidence of Liver Flukes and Gastro-Intestinal Parasites in Cattle, Department of Medicine, Faculty of Veterinary Science, Bangladesh Agricultural University, Mymensingh-2202, Bangladesh.
- Sahba, G. H., Arfaa, F., Farahmandian, I., Jalali, H. (1972). Animal Fascioliasis in Khuzestan, Southwestern Iran. J. Parasit. 58(4); 712-716. Vet. Bull. 1973.43:233.

- Saleha, A. A. (1991). Liver fluke disease (fascioliasis):epidemiology, economic impact and public health significance. 1991 Dec; 22 Suppl: 361-4.
- Schillhorn van Veen, T. W., Folaranmi D. O. B., Usman S. and Ishaya T., (1979). Incidence of liver fluke infections (*Fasciola gigantica* and *Dicrocoelium hospes*) in ruminants in northern Nigeria. Vol 12, Pp 97-104
- Sengupta, T. and Iyer, P.K. R. (1968). Studies on the pathology of buffalo livers infested with *fasciola gigantica*. Ind. J. Anim. Hlth. 7(1):111-119.
- Sevinc, M., Basoglu, A. (2002). Fatty liver in periparturient diseases of dairy cows. Vol. 79(12) Pp 59-61.
- Shaikh, H.U., Huq, M.M, Karim, M.K., and Khan, M.M.M. (1983). Parasites of zoonotic importance in domesticated ruminants. Pakistan Vet. J. 3(1): 23-25.
- Sheikh, SA. and Hussain, MS. (1968). Incidence of hydatidosis in livestock in Lahore. Pak. Jour. Ani. Sci. 19: 139-142.
- Shiri, W. (1963). Histopathological studies studies on bovine liver affected by *fasciola hepatica* with spetial reference to the brilliant cells. Jap. J. vet. Sci. 25; 193-199.
- Simesen, M. G. (1968). Chronic fascioliasis in sheep. I. Clinical, Clinical-pathological and histopathological studies. Helm. Abstr. 40 (4); No. 4850(1971).
- Smith, H. A., Jones, T. C., and Hunt, R. D. (1972). *Veterinary Pathology*, 4th edn. Lea and Febiger, Philadelphia, pp.715-716, 794-800, and 1230-1231.
- Solo, T., Fujii, H., Sakae, K. and Isoda, M. (1978). Acute fascioliasis in dairy cattle. Helm. Abstr. 48(8): No. 3836(1979).
- Soulsby, E.J.L. (1982). *Helminthes, Arthropods and protozoa of Domesticated Animals*, 7th edn. The English language Book society and Baillire Tindal. London; Pp 51-65.

- Stenious, P. I. (1963). Parasitic diseases in the liver. Studies on sheep. Int. vet. Congr. (17th). Hanover, August 14-21. Proceeding, Vol. 1. Pp. 739-742.
- Sugiura, K. (1960b). Studies on treatment of fascioliasis II clinical and pathological studies: liver lesions in cattle. Bull. of nati. Int. Inst. of anim. Hlth. Tokyo. 39; 149-159. Helm. Abstr. 34(2): 1327 (1964).
- Sundaram, R. H. and Natarajan, R. (1960). A Study of the Incidence of hydatid disease in cattle and buffalo in the city of the Madras. Indian Vet. J. 37(1): 19-24.
- Swai, E. S. and Ulicky, E. (2009). An evaluation of the economic losses resulting from condemnation of cattle livers and loss of carcass weight due to Fasciolosis: a case study from Hai town abattoir, Kilimanjaro region, Tanzania. 21 (11) 2009.
- Swai, E. S., Mtui, P. F., Mbise, A. N., Kaaya, E., Sanka, P. and Loomu, PM. (2006). Prevalence of gastro intestinal parasite infections in Maasai cattle in Ngorongoro District, Tanzania. Livest Res Rural Dev 18: 107, 2006.
- Swarup, D., Pachauri. S. P., and Mukherjee, S. C. (1987). Prevalence and clinic pathology of naturally occurring fascioliasis and biliary apmhistomiasis in buffaloes. Indian J. Anim. Sci. 57(4): 252-256.
- Trifonov, T.P. (1980). Helminth infections in the liver of sheep. Helm. Abstr. 49(3); No. 1058 (1980).
- Tsretaeva, N.P. and Gumenchikova, V.P. (1965). Pathology and histochemistry of the liver of sheep with acute or chronic Fascioliasis following single infection, Superinfection and reinfection. Master. Konf, Vses. Obshch-Gelmint.
- Upadhyay, A. N., Sahai, B. N. (1986). Studies on Gigantocotyl explanatum; Nasmark: Indence in cattle and Buffaloes and development of miracidium. Ind. J. Anim. Hlth. 25(1):55-59.

- Upadhyay, A. N., Parasad, B., Hha, G. J. and Sahai, B. N. (1987). Histochemistry and histopathology of liver of buffalo's naturally infected with *Gigantocotyl explanatum*. *Ind. J. Anim. Sci.* 57(3) 180-185.
- Uzoukwu, M. and Ikeme, M. M. (1978). Hepatic changes in natural. *Fasciola gigantica* infections of Fulani Zebu. *Helm. Abstr.* 1979. 48(9): 4574.
- Verma, T. K. (1978). Hydatid diseases in food animals and man *Livestock Adviser, Bangalors.* 3(4): 17-19. *Helm. Abstr.* 1980. 49(3):1121.
- Verster, A. (1961). Helminth research in south Africa. V. *Echinococcus* in south Africa. *Jour. South. Afri. Vet. Med. Asso.*, 32 (2): 181-185. *Helm. Abst.* 31 (1962) No.262
- Wensvoort, P. Over, H. J. and Straien, M. J. (1980). *Perilobular fibrosis in chronic bovine fasciolosis.* *Veterinary quarterly* 1(2):75-81 *Helm. Abstr.* 1980. 49(4); 1581.
- Yaman, F. M., Assaf, L., Hailat, N. and Abdel-Hafez, S. K. (1985). Prevalence of hydatidosis in slaughtered animals from North Jordan. 1985 Oct; 79(5):501-6.

